

RESTORING THE INTRARADICULAR SPACE: ESTHETIC POST SYSTEMS

Douglas A. Terry, DDS


Private Practice
Houston, Texas

Adjunct Professor
Department of Restorative Sciences
University of Alabama at Birmingham
Birmingham, Alabama

Professor Emeritus
Department of Restorative & Esthetic Dentistry
V.S. Dental College & Hospital
Rajiv Gandhi University of Health Sciences
Bengaluru, India

 **QUINTESSENCE PUBLISHING**

Berlin | Chicago | Tokyo
Barcelona | London | Milan | Mexico City | Moscow | Paris | Prague | Seoul | Warsaw
Beijing | Istanbul | Sao Paulo | Zagreb



Library of Congress Cataloging-in-Publication Data

Names: Terry, Douglas A., author.

Title: Restoring the intraradicular space : esthetic post systems / Douglas A. Terry.

Description: Batavia, IL : Quintessence Publishing Co, Inc, [2021] |

Includes bibliographical references and index. | Summary: "This book describes the biologic basis for restoring weakened teeth with post and core systems, focusing on how to do this conservatively and esthetically to maximize longevity"-- Provided by publisher.

Identifiers: LCCN 2020050058 | ISBN 9781647240561 (hardcover)

Subjects: MESH: Post and Core Technique | Dental Restoration, Permanent | Esthetics, Dental | Root Canal Therapy

Classification: LCC RK652.5 | NLM WU 515 | DDC 617.6/95--dc23

LC record available at <https://lcn.loc.gov/2020050058>



©2021 Quintessence Publishing Co, Inc

Quintessence Publishing Co, Inc

411 N Raddant Rd

Batavia, IL 60510

www.quintpub.com

5 4 3 2 1

All rights reserved. This book or any part thereof may not be reproduced, stored in a retrieval system, or transmitted in any form or by any means, electronic, mechanical, photocopying, or otherwise, without prior written permission of the publisher.

Editor: Leah Huffman

Design: Sue Zubek

Production: Sue Robinson

Printed in China

CONTENTS

Foreword vi

Preface viii

Contributors x

1

ESTHETIC POST SYSTEMS 1

2

THE ADHESIVE DESIGN CONCEPT 61

3

CLINICAL APPLICATIONS FOR RESTORING
“COMPROMISED” ENDODONTICALLY
TREATED TEETH 127

4

CLINICAL APPLICATIONS FOR RESTORING
“END STAGE” ENDODONTICALLY
TREATED TEETH 207

Index 251



Scan this QR code to access
additional scientific content.

FOREWORD



There is a question I always ask myself, my students, and my colleagues: “What is our single most important responsibility as an oral health care provider?” While there may be various interpretations of our core duties, I always come to the same simple but resounding answer: “To help our patients keep their teeth as long as possible!”

To pursue this goal and preserve teeth, we have to emerge from the era of destructive dentistry, which dates back to times before resin bonding and adhesive protocols were available. Healthy tooth structure had to be sacrificed during preparation to accommodate restorative and prosthetic materials that relied solely on retention. The popularity of implant dentistry sometimes added to this destructive mindset when teeth were extracted and implants placed too early or inadequately, thereby accelerating the cascade of early tooth loss instead of following the core principle of preservation. The rush to the seemingly easiest but most destructive treatment options may lead to early tooth loss, bone and tissue resorption, peri-implantitis, and altered eruption of teeth next to implants that were placed in younger patients.

Several new studies agree that the recommended age when dental implants can be placed safely is going up and

up, making a strong case to preserve even severely damaged and endodontically treated teeth as long as possible. Don’t get me wrong: I have nothing against implants, and in many cases, they are the last and absolutely best resort to provide our patients with chewing function and esthetics. However, they are the last resort when everything else fails. And the argument I often hear that “implants last longer than teeth” is not only completely wrong but not even a logical argument for erring on the side of placing implants earlier instead of exploiting all resources to try and save a natural tooth. While some of that rationale may, sadly, be driven by convenience and economic aspects, I believe that the most important factors in the treatment-planning decision-making process are proper knowledge and information.

The most difficult treatment-planning decisions are related to the severely damaged endodontically treated tooth. The amount of misinformation on this topic is simply astonishing. What is the state of the scientific evidence on endodontically treated teeth and how to restore them? When should a post be placed? And in light of this era of minimally invasive and adhesive dentistry, what are the best materials and most current protocols for post and core placement, based on the science?

Douglas, author of many groundbreaking and bestselling books, has compiled a team of the most respected researchers and clinicians to answer these questions and provide clear guidance on a topic that seems to have been widely overlooked. *Restoring the Intraradicular Space:*

Esthetic Post Systems provides a detailed and scientific description of the evolution of post and core systems while offering a comprehensive view into all associated aspects, from general design criteria and the components of the post and core systems to post materials, adhesive bonding and luting agents, material selection, core buildup, and finally, the extracoronary restoration. The dilemma of preserving or replacing the compromised natural tooth is discussed in great detail with ample scientific support. Over 1,000 cited research studies are distilled into clear and meaningful guidelines for the clinician to select an appropriate system for the restorative management of endodontically treated teeth for each clinical situation. In well-known Douglas Terry manner, clinical protocols are illustrated meticulously and with stunning quality with over 800 photographs and figures.

To fulfill our responsibility to help patients keep their teeth as long as possible, understanding and selecting proper protocols, materials, and procedures to restore endodontically treated teeth is indispensable. While a comprehensive text on this topic was long overdue, *Restoring the Intraradicular Space: Esthetic Post Systems* is not only an exceptional

resource for the practicing dentist but a true masterpiece in its scientific rigor and clinical excellence. The captivating writing and superb clinical documentation make this an essential piece of literature for oral health care providers at any stage of their career. Congratulations Douglas and team—I am sure that your work will inspire countless colleagues and prevent many patients from losing their teeth too early. Thank you for that!

A handwritten signature in black ink, appearing to read 'Markus B. Blatz', with a long, sweeping horizontal line extending to the right.

Markus B. Blatz, DMD, PhD, Dr med dent habil

Chairman, Department of Preventive and Restorative Sciences

Assistant Dean for Digital Technologies and Professional Development

University of Pennsylvania School of Dental Medicine

PREFACE



Recently I read a comment by a dentist saying “every root has a chance.” This statement resonated with my philosophy because it is not only the tooth but also the alveolar and soft tissue architecture and the patient that deserve a chance. Over the last decade I have witnessed patients presenting with fractured teeth that were referred for removal and implant

placement. Upon discussion with them, it became clear that not everyone was given proper informed consent; some were offered only the one treatment option. So I would explain the how’s and why’s of every option, and then the patient could make the proper choice for their oral health. Individuals make better decisions when they are given all the potential options and the consequences of each.

A recent conversation with a young periodontist on my team further underscored this problem. He told me that his referring dentists do not try and save a given tooth with a post and core. In discussing this with my friend and colleague Dr Konrad Meyenberg in Switzerland, we considered that perhaps the reason was the lack of confidence clinicians have in the endodontic therapy and in their knowledge of proper adhesive protocol. This extraction-oriented, reconstructive mentality may be based on the clinicians’ misconception that endodontically treated teeth are considered inferior to implants in regard to long-term stability and retention. However, it has been demonstrated that endodontic and implant therapies have equivalent results when

the treatments are appropriately chosen and performed at a high level of expertise on well-maintained patients.

Throughout these chapters, I would like the reader to direct their attention to modern applications in the fields of endodontics, restorative dentistry, periodontics, and orthodontics. In the past two decades, dentistry has seen a paradigm shift in philosophy that has been guided by a greater understanding of science. Advancements in endodontic technology with the use of modern instruments and new equipment, biocompatible filling materials, and microsurgical techniques have allowed the clinician to visualize, identify, and treat complexities they could not have fathomed a decade before. Correspondingly, advancements in restorative material formulations, adhesive technology, and a better understanding of the methods to achieve a biologically stable, dentogingival interface through periodontal and orthodontic concepts have expanded the treatment possibilities for the patient, clinician, and technician. Furthermore, clinicians should not make treatment decisions based on their skill level alone but should refer or adopt an interdisciplinary approach when required for the management of more complex clinical scenarios.

These advances in all disciplines in the 21st century have increased the myriad opportunities available to discriminating patients and provided solutions to many of the endodontic, restorative, and esthetic challenges faced by the restorative team. This changing technology has allowed the clinician to treat many clinical challenges through simpler, more conservative, and more economical methods. This evolution in philosophy and science has resulted in a change in the trend for dental treatment. Thus, an awareness in the evolution of different disciplines in dentistry

combined with the common occurrence of misinformed patients coming for another opinion stimulated my team and me to develop this book. This philosophy of choosing the least invasive procedure and moving to a more invasive one if required over time is an ethical one. I hope the concepts in this book direct the clinician and technician to consider possibilities they had not imagined.

The text provides a detailed and scientific description of the evolution of the post and core system and the significance of the adhesive design concept when restoring the intraradicular post space. A detailed presentation is provided of the various applications and restorative techniques that I use on a daily basis with my patients for restoring the post space. The scientific data and microscopic illustrations are intertwined to provide clarity and evidence for these procedures. In addition, chapter 2 provides a detailed description of the light-curing unit (by Dr Richard Price) and the significance of understanding its mechanism for proper selection and use, which play an integral role in the adhesive design concept for achieving an optimal bonded interface. The third chapter demonstrates the information presented in the early chapters through illustrated case presentations while providing clinical applications for retaining the compromised tooth. The last chapter demonstrates clinical scenarios for the replacement and restoration of the nonrestorable endodontically treated tooth or the “end stage” tooth, while providing various treatment considerations and the critical factors that may play a role in the selection, outcome, and predictability of each of these treatment modalities.

Acknowledgments

As always, the inspiration for writing this book and sharing photographs of these procedures can be attributed to my dear patients, colleagues, and students around the world who have directed me on this journey. Compilation of this information would not have been possible without the dedication, persistence, and relentless hard work and long hours of my dear friend and personal assistant, Melissa Nix. My mother’s great ability to persuade patients to return for follow-up photographs along with her support and delicious dinners and desserts for the team have certainly been crucial for completing this project. Furthermore, this book would not have seen the light of day without the dedication, attention to detail, and organization and imagination of the Quintessence team. I would also like to express my gratitude to my team members who are my true friends—Dr John Powers, Dr John Burgess, Dr Ruhani Cheema, Dr Markus Blatz, Dr Susana Paoloski, Dr Gamid Nasuev, Alex Schueger, Olivier Tric, and Dr Richard Price. Also, I would like to thank my wonderful patients, without whom this project would not have been possible. Finally, I give special thanks to my Creator who instills passion in my life for everything I do and who makes me realize that teeth are simple in His hands but so complex in mine.



CONTRIBUTORS

Editorial Reviewers

John O. Burgess, DDS, MS
John M. Powers, PhD
Richard Price, BDS, DDS, MS, PhD
Susana B. Paoloski, DDS
Markus B. Blatz, DMD, PhD, Dr med dent habil

Scientific Reviewers and Contributors

Irfan Ahmad, BDS
Maciej Zarow, DDS, PhD
Norman Hicks

Clinical and Laboratory Contributors

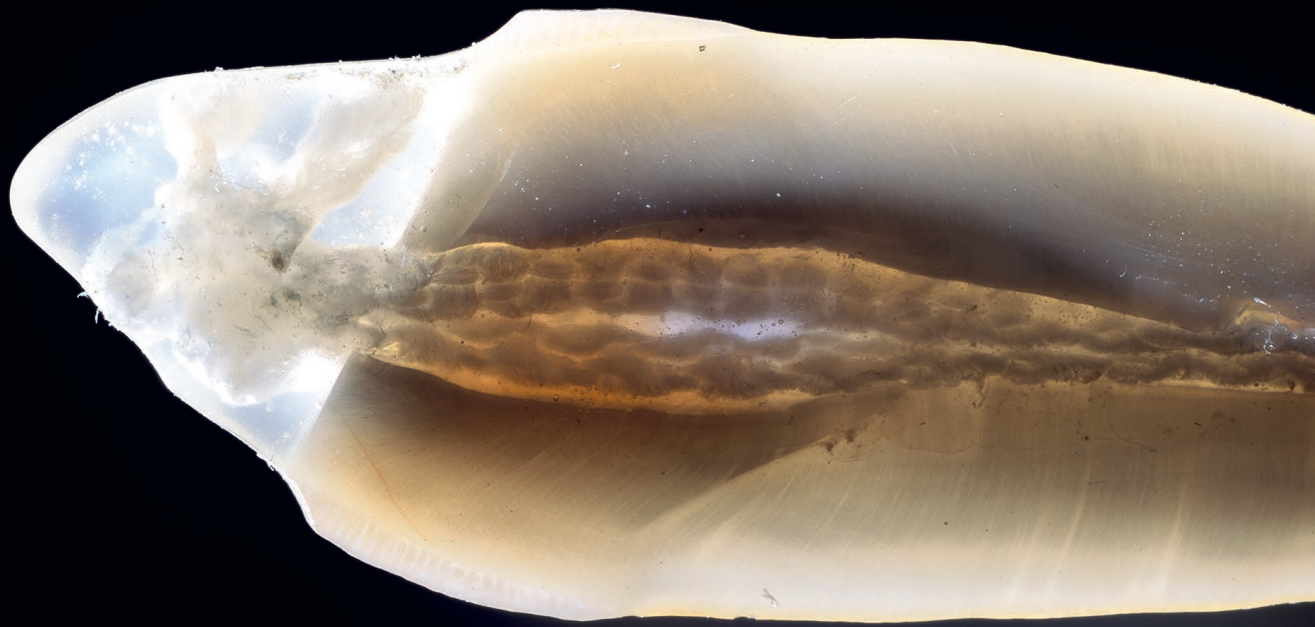Abdelrahman Awadin, BDS
August Bruguera, CDT
Victor Castro, CDT
Ruhani Cheema, BDS, MDS, MS
Jungo Endo, RDT
Manish Garala, BDS, MS
Kim S. Gee, DDS, MS
Gamid Nasuev, DDS, PhD
Wesam Salha, DDS, MSD
Alex H. Schuerger, CDT
Ritu Sharma, BDS, MDS
Riccardo Tonini, MD, DDS
Olivier Tric, MDT
Islam S. Zakzouk, BDS

[illegible]

“What is truth” is a question that has been asked by philosophers, scientists, and religious prophets for centuries.

better understanding and application. Relative truth conforms to logic and reality and can be interpreted differently by every person based upon their culture, religion, and life experiences. However, absolute truth requires each of us to search and discover something greater than ourselves.

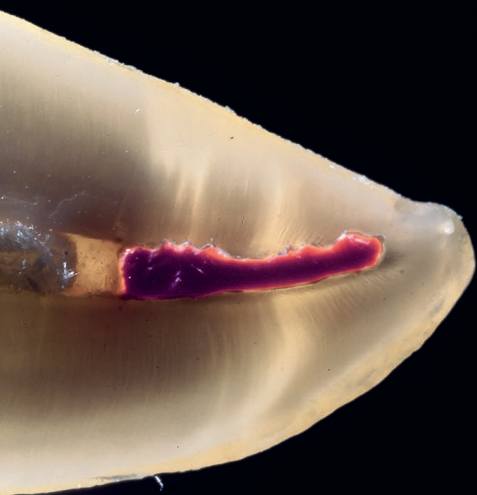God is the true essence of being and the absolute truth. The Bible describes the ultimate expression of truth in John 14:6: "I am the way, the truth, and the life."



Photography by Irfan Ahmad, BDS

1

ESTHETIC POST SYSTEMS



HISTORICAL PERSPECTIVE

For over 250 years, clinicians have written about the placement of posts in the roots of teeth to retain restorations.^{1,2} As early as 1728, Pierre Fauchard described the use of “tenons,” or metal posts screwed into the roots of teeth to retain bridges.^{1,3–6} In the mid 1800s, wood replaced metal as the post material, and the “pivot crown” became popular among dentists; this was a wooden post fitted to an artificial crown and the canal of the root.^{1,2,7} Often these wooden posts would absorb fluids and expand, frequently causing root fractures.^{4,7} In the late 19th century, the “Richmond crown,” a single-piece post-retained crown with a porcelain facing, was engineered to function as a bridge retainer.^{2,7} During the 1930s, the custom-cast post and core was developed to replace the one-piece post crowns. This procedure required casting a post and core as a separate component from the crown.⁷ This two-step technique improved marginal adaptation, allowed variation in the path of insertion of the crown,¹ and provided a better alignment of the core when the tooth being restored was flared or overlapped the adjacent tooth. In the 1990s, tooth-colored fiber posts debuted as an alternative to these conventional metal post systems.^{8–17}

From the past to the present, the rationale for the utilization of a post system has metamorphosed. The concepts of the past were designed with the belief that endodontically treated teeth (ETT) were brittle from a loss of moisture^{18,19} and required a post to strengthen the weakened tooth.^{20–26} Although there is a reduction in moisture content after endodontic treatment, current concepts refute this postulate.^{18,19,27–36} Current concepts supported by evidence-based research indicate that the primary objective of any post and core system is to replace missing coronal tooth structure, to retain the core,^{37–44} and to provide sufficient retention^{41,43,45–54} and resistance form to the final restoration to restore original form and function.^{37–39,55–69} Today, clinicians can choose from a variety of user-friendly post and core systems^{29,70–81} for different endodontic, restorative, and esthetic requirements. These systems and methods are well documented in the literature.^{23–25,29,40,42,80–99} However, no

single post system meets the demands for favorable biomechanical compatibility^{65,80,100–102} or provides the perfect restorative solution for every clinical circumstance, and each situation requires an individual evaluation.⁸²

Furthermore, the reconstruction of ETT can present restorative and esthetic challenges for the technician and the clinician.^{9,80,103–105} The failure of these post-retained systems has been documented in numerous clinical studies.^{22,39,45,51,66–68,101,106–150} Many of these studies indicate that the failure rate of restorations on pulpless teeth with posts and cores is higher than that for restorations of vital teeth^{106,151–163} because of their structural differences and the significant loss of tissue.³⁶ Several main causes of failure of post-retained restorations have been identified, including recurrent caries,^{164,165} endodontic failure,¹⁶⁵ periodontal disease,¹⁶⁵ post dislodgment,¹⁶⁵ cement failure,¹⁶⁶ post-core separation,¹⁶⁵ crown-core separation,¹⁶⁵ loss of post retention,^{40,164} core fracture,¹⁵² loss of crown retention,^{40,164} post distortion,¹⁶⁴ post fracture,^{40,152,164,166} tooth fracture,^{152,166} root perforation,⁴⁰ and root fracture.^{40,152,164,167,168} Also, corrosion of metal posts has been proposed as a cause of root fracture.¹⁵² A post and core system fabricated with dissimilar metals can cause galvanic corrosion that occurs between the two dissimilar materials.^{19,169} This gradual destructive process involves the electrical interaction of at least two different metals or nonmetallic conductors in an environment (ie, microleakage) that accelerates the corrosion of at least one of them, while the least noble metal corrodes the most (for more information, see the section entitled “Lack of corrosiveness” later in this chapter).

The traditional custom-cast dowel core provides a better geometric adaptation to excessively flared or elliptical canals and almost always requires minimal removal of tooth structure.¹ Custom-cast posts and cores adapt well to extremely tapered canals or those with a noncircular cross section and/or irregular shape and roots with minimal remaining coronal tooth structure.^{82,89} Patterns for custom-cast posts can be formed either directly in the mouth or indirectly in the laboratory. Regardless, this method requires two appointment visits and a laboratory fee. Also, because it is cast in an alloy with a modulus of elasticity that can be as

high as 10 times greater than that of natural dentin,⁵⁵ this possible incompatibility and rigidity can create stress concentrations in the less rigid root, resulting in post separation or failure.^{170–172} Additionally, the transmission of occlusal forces through the metal core can focus stresses at specific regions of the root, causing root fracture⁵⁵ (Fig 1-1). Furthermore, upon esthetic consideration, the cast-metal post can result in discoloration and shadowing of the gingiva and the cervical aspect of the tooth¹⁷³ (Fig 1-2).

An alternative and currently more popular method is the prefabricated post and core system. Prefabricated post and core systems are classified according to their geometry (ie, shape and surface configuration) and method of retention. The methods of retention are designated as active or passive. Active posts engage the dentinal walls of the post space preparation during cementation, whereas passive posts do not engage the dentin but rely on cement for retention.^{1,174} The basic post shapes and surface configurations are tapered serrated, tapered smooth-sided, tapered threaded, parallel serrated, parallel smooth-sided, and parallel threaded. While active or threaded posts are more retentive^{175–178} than passive posts, active posts create high stress concentrations in root dentin at each thread during placement.^{177,179–184} These stresses have the potential to create cracks^{185,186} that can increase the susceptibility of root fracture^{127,184} when occlusal forces are applied.¹⁰ Thus, a significant cause of failure with an active post system is root fracture.^{52,184,187,188} More recent modern designs provide a collar that limits insertion, flexible tips (FlexiPost), and stress-reducing thread design. Metal screws have a survival rate of 78%^{127,184} after 1 year and 50% after 5 years.¹⁸⁴

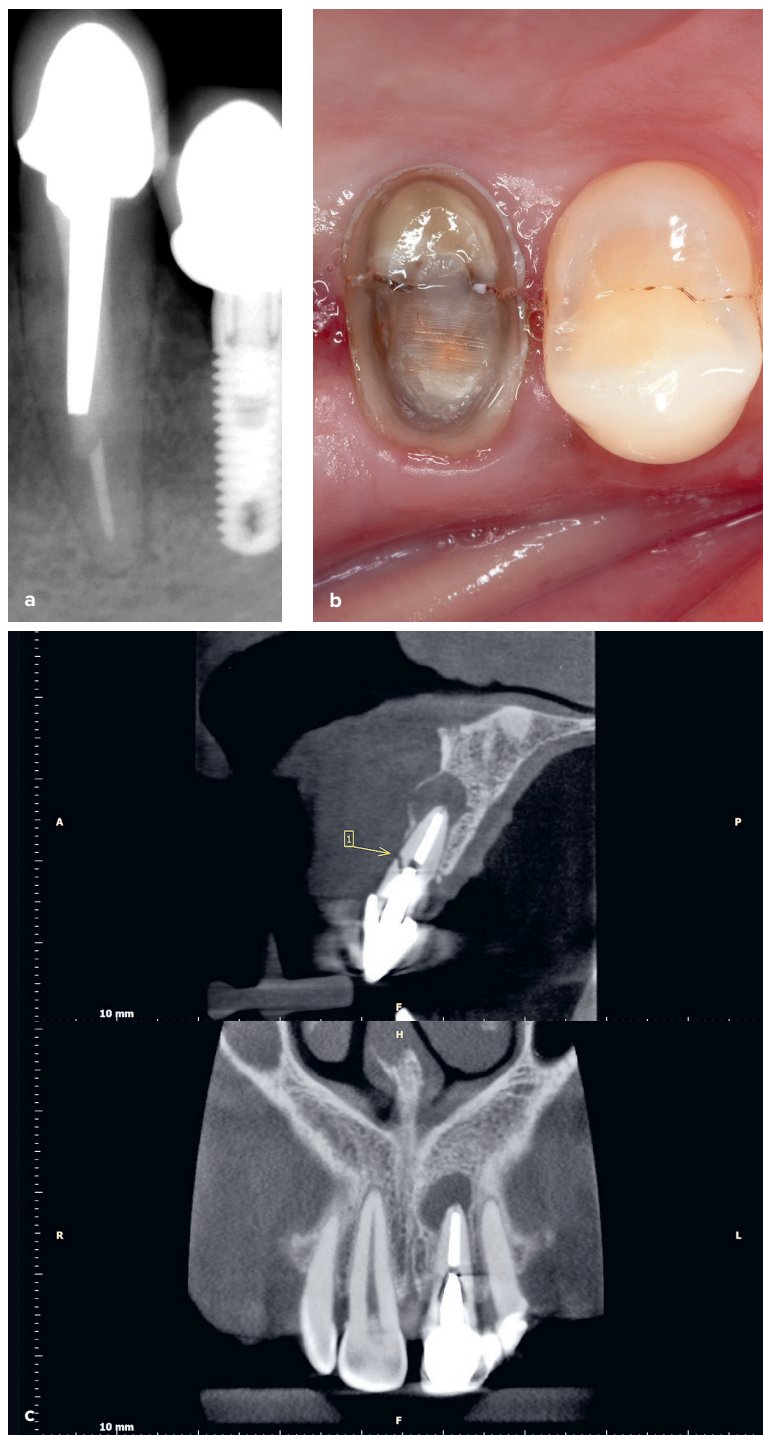


Fig 1-1 (a) Occlusal forces are transmitted through the metal post in the mandibular right canine, and stress concentrations are focused in the mesial aspect of the apical one-third of the root, resulting in a horizontal fracture. (b) A vertical fracture occurs in the maxillary right second premolar with a metal post present. (c) A CBCT shows a horizontal fracture in the maxillary left central incisor. (Radiograph courtesy of Ritu Sharma, BDS, MDS.)

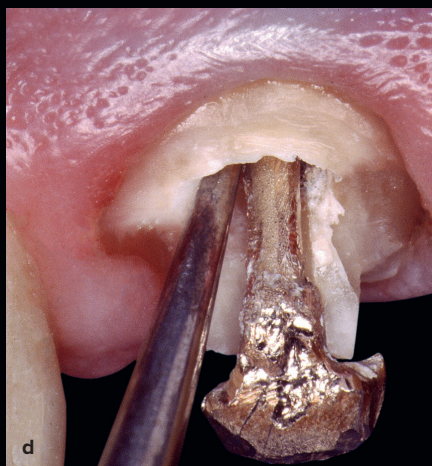
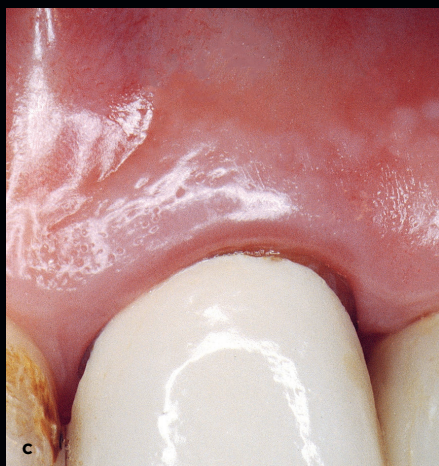
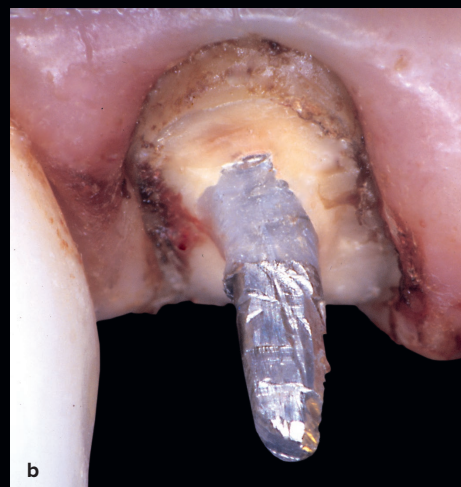
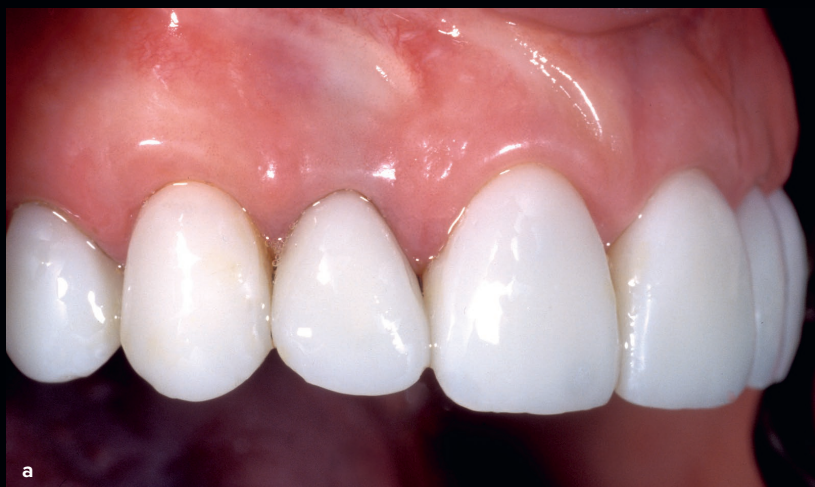
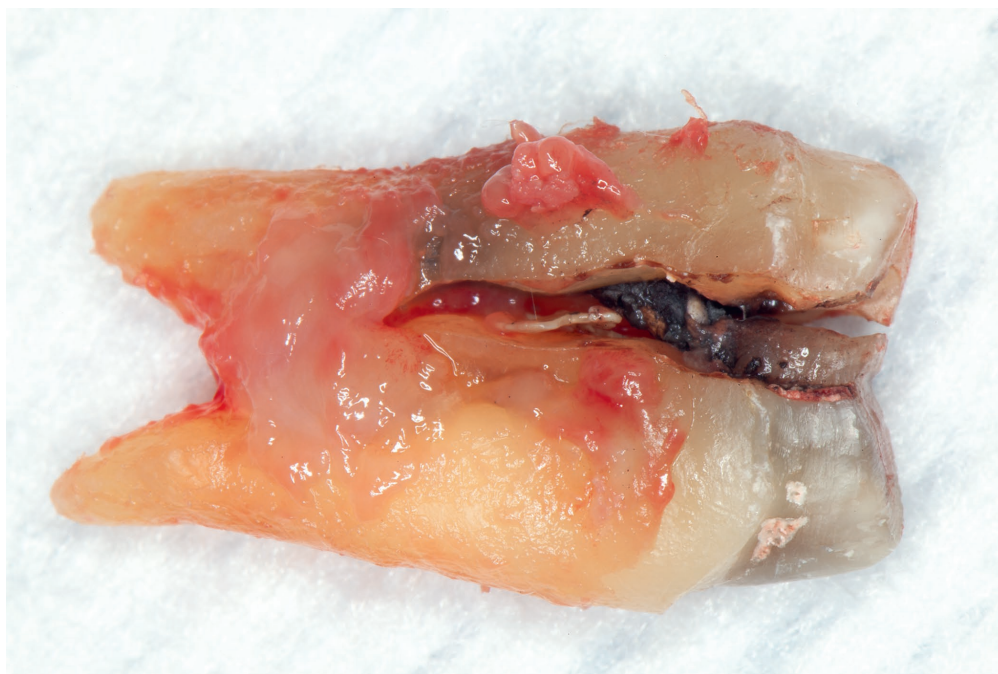
Fig 1-2 (a and b) A maxillary right lateral incisor is restored with a cast-metal post. This can result in discoloration and shadowing of the gingiva and the cervical aspect of the tooth. (c to e) The incidental light is completely blocked by the metal post and the underlying metal framework of the crown, which causes the characteristic shadow at the submarginal zone.



Fig 1-3 Posts and cores fabricated from materials with a high modulus of elasticity and a combination of noble and non-noble alloys in the oral environment may result in electrochemical reactions such as corrosion of metals, which can cause root fracture.



Parallel-sided serrated posts are the most retentive of the passive prefabricated posts, and the tapered smooth-sided posts are the least retentive of all designs.⁷

Traditional prefabricated metal posts are made of platinum-gold-palladium, brass, nickel-chromium (stainless steel), pure titanium, titanium alloys, and chromium alloys.^{7,37–39,164} Although stainless steel is stronger, the potential for adverse tissue responses to the nickel has resulted in the use of a biocompatible titanium alloy.^{189,190} Also, contributing factors to root fracture such as excessive stiffness (modulus of elasticity)^{191–193} and post corrosion^{7,121} (Fig 1-3) from many of these metal posts have generated concerns about their use. In addition, prefabricated metal posts can negatively affect the esthetic result.

Nonmetallic prefabricated posts have been developed as alternatives,¹⁹⁴ including ceramic (white zirconia) posts, carbon-fiber posts, and fiber-reinforced resin posts. Zirconia posts have a high flexural strength and are biocompatible as well as corrosion resistant.¹⁹⁵ This material, however, is difficult to section intraorally with a diamond bur and difficult

to remove from the canal for retreatment.¹⁶⁴ Carbon-fiber posts are made from unidirectional carbon fibers held together with an epoxy resin and ceramic. They exhibit strength and relatively high flexibility and can be retrieved from the canal preparation with ease for retreatment. However, their black color has a negative effect on the final esthetic result of all-ceramic crowns.¹⁸⁹ New advances with next-generation tooth-colored posts, which are identical in design to conventional carbon-fiber posts, reduce this esthetic challenge. There are several methods for the fabrication of the direct fiber-reinforced resin system that include a bondable polyethylene woven reinforcement fiber (Ribbond-THM, Ribbond; Construct, Kerr/Sybron), a prefabricated fiber-reinforced composite post system, a direct anatomical formed fiber-reinforced composite post system,^{105,195,196} a direct/indirect anatomical formed fiber-reinforced composite post system, and an indirect anatomical formed fiber-reinforced composite post system (see the section entitled “Direct Fiber-Reinforced Post and Core System” later in this chapter).

CONSIDERATIONS FOR THE SELECTION OF RESTORATIVE MATERIALS

As the clinician continues the search for optimal functional and esthetic success with a post-retained crown system, the current selection of restorative materials and techniques may prove overwhelming. While no single system provides the ideal restorative solution for every clinical circumstance, understanding both general design criteria and the components for the various post and core systems available allows the clinician to appropriately select the method and materials compatible with the existing tooth structure and desired result. A *system* is defined as any set of components working together for the overall objective of the whole.¹ Selecting the proper post and core system for a specific clinical situation requires an evaluation of the various components and interfaces of the system.^{197,198} The components of the direct fiber-reinforced composite resin post system are the surface of the root dentin, the intraradicular post, the core buildup, the luting cement, and the final restoration¹⁹⁹ (Fig 1-4). The system can be analyzed in four regions: (1) at the intraradicular surface (dentin surface), (2) at the post-tooth interface, (3) within the core, and (4) intracoronally. For the successful rehabilitation of the ETT, it is imperative to understand the disparity and complexity of the interrelationship of these interfaces with various restorative materials.⁵⁵ The failures of each system provide us with design principles that can be utilized with any post-retained crown system. These specific design principles bring us to higher levels of understanding potential problem areas in any restorative situation. Therefore, the following design principles should be considered when using any post-retained crown system. An evaluation of the direct fiber-reinforced resin post system with these design principles is provided.

Maximum post retention and core stability

Dislodgment and tooth fracture are causes for failure of post and core restorations. The majority of clinical failures involving fiber-reinforced post systems occur through debonding.^{15,29,45,80,100,119,120,124–126,200–215} Core stability and post retention are important in preventing these failures in the restoration of ETT^{51,105,164,166,168,177,193,216–218} (Fig 1-5). The ideal post system should replace lost tooth structure while providing adequate retention and resistance for the core and final restoration while transferring occlusal forces during function and parafunction to prevent root fracture. Adhesive post systems allow conservative minimally invasive preparations that preserve sound tooth structure and strengthen the remaining tooth. However, meticulous adhesive protocols are required for reliable bonding and effective adhesion. Improving the quality of the adhesive interface and the long-term adhesion of fiber-reinforced post systems to dentin requires improving resin impregnation into dentin,^{212,219–227} enhancing the strength of the polymer formed by the adhesive system,^{212,228–252} and increasing the resistance of collagen fibrils to enzymatic degradation.^{212,253–273} Because the root canal anatomy can impose limitations to achieving a quality hybrid layer, modified clinical protocols have been suggested. Studies indicate that various methods and materials can improve the stability of the resin-dentin bond.

Numerous studies suggest methods and materials to improve resin impregnation into dentin. One study indicates that diamond bur preparation of the post channel in comparison to a carbide bur allows the etching procedure to remove the smear layer more efficiently with more open dentinal tubules and with fewer smear layer remnants. Thus, the acid-resistant smear layer produced by the manufacturer's carbide bur for post space preparation can be removed with a similar-diameter diamond bur, and the replaced smear layer will be more susceptible to phosphoric acid dissolution.^{212,220} Other studies indicate that liquid phosphoric acid applied with an endodontic needle improved the removal of the smear layer better than

Fig 1-4 The five components of the post-retained crown system are the internal root dentin surface, luting cement, intraradicular post, core buildup, and the crown. The system can be analyzed at each of the four interfaces: at the dentin surface, at the post-tooth interface, within the core, and intracoronally.

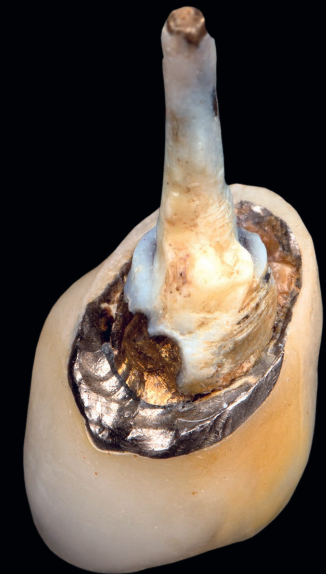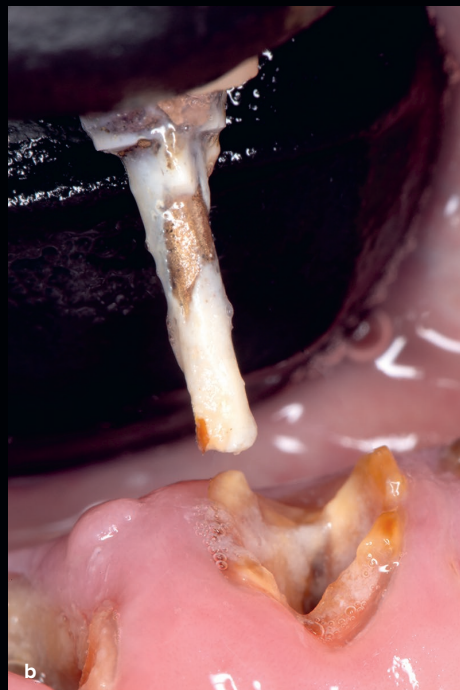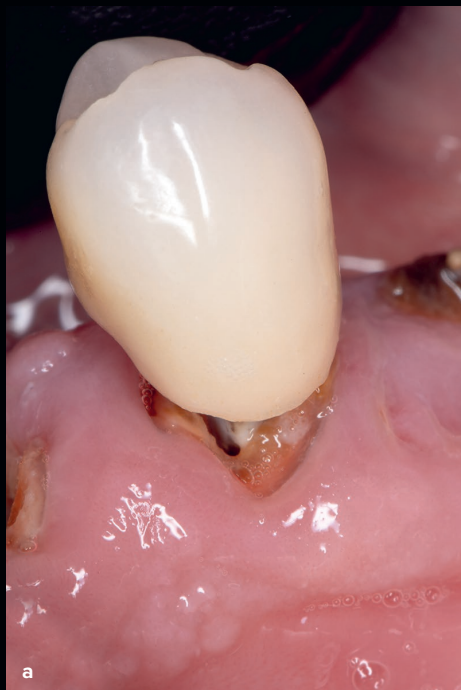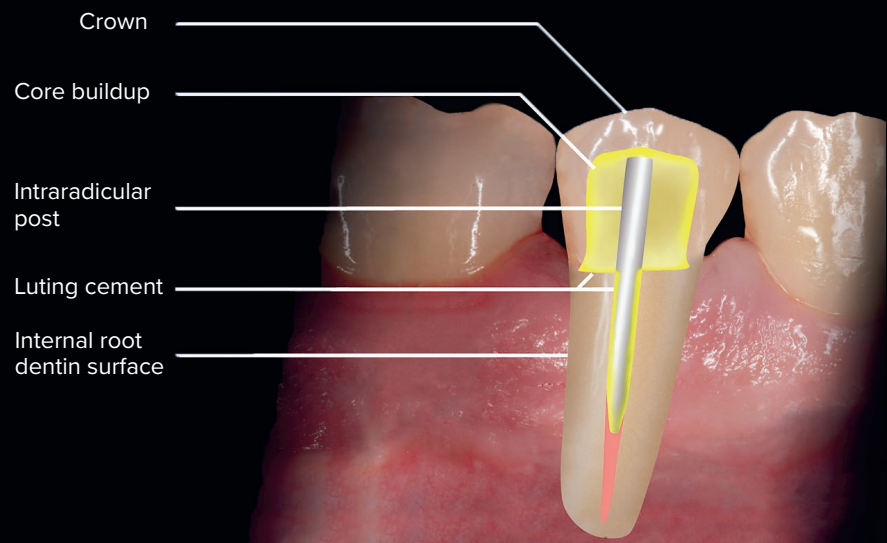


Fig 1-5 (a to c) Failure of a post-retained system. The metal-ceramic crown with gold post dislodges from the intraradicular space as a result of microleakage and recurrent caries at the interface.

gel etchants and that higher bond strengths to the dentin were achieved when an etch-and-rinse adhesive system was utilized.^{212,226,227} Several studies indicate that vigorous rubbing of the adhesive may improve the permeability of the etchant into the dentin collagen network.^{223,224} Other studies indicate that the application of multiple layers of simplified etch-and-rinse adhesives and self-etch adhesives to coronal dentin yield higher immediate bond strengths.^{221,222} However, this modified protocol should be applied with caution to prevent post seating because of the increase in thickness of the hybrid layer. It is suggested that paper points or a vacuum capillary tip adapter (Luer Vacuum Adapter, Ultradent) can be utilized to absorb the excess solvent.²¹²

Various studies suggest methods and materials to enhance the strength of the polymer formed by the adhesive system. Studies indicate that the use of a hydrophobic coating after the application of a simplified self-etch adhesive and an etch-and-rinse adhesive system provides a thicker and more uniform adhesive layer with lower concentrations of water and solvent and thus a significant reduction in fluid flow rate.^{235,240} This procedure transforms a simple-layer adhesive into a multilayer adhesive. This method ensures that the hydrophilic layer is photoactivated prior to the application of the hydrophobic, non-solvated bonding resin. This allows for the simplified adhesive layer to be more concentrated with hydrophobic monomers from the additional coating.^{212,232,241} Thus, by reducing the concentration of unreacted monomers between the primed and bonded layers, a more compacted and stable resin-dentin interface can be achieved.^{212,235} However, this modified protocol should be applied with caution to prevent a thick adhesive layer that could interfere with post seating.²¹² Numerous studies suggest that the application of ethanol to replace water in acid-etched collagen will allow hydrophobic resins to infiltrate the demineralized dentin and create a hydrophobic hybrid layer.^{231,239,242,252} Because endogenous matrix metalloproteinases (MMPs) become inactive in the absence of water, one study suggests that the application of ethanol is a potential mechanism for increasing the longevity^{212,250} and durability^{274–276} of resin-dentin bonds. However, several

authors indicate that ethanol wet bonding yielded higher immediate bond strengths and resulted in lower nanoleakage in root canals.^{237,246} Although there are differences in the suggested protocol in regard to concentration and time of application, a recent study suggested a simple higher concentration (50%) of ethanol for 60 seconds.²⁶⁶ Others indicate that using a high-intensity light-curing unit and/or increasing the irradiation time for the adhesive systems and resin cements will improve the adhesion of these systems to the canal wall dentin.^{228,230,244,249} One paper indicated that increasing the light-curing time improved bond strengths to root dentin.²²⁹

A myriad of studies suggests methods and materials for increasing the longevity of hybridization by improving the resistance of collagen fibrils to enzymatic degradation.^{207,277,278} Several studies suggest the application of chlorhexidine (CHX) as a protease inhibitor for MMPs²⁶¹ and cysteine cathepsins²⁷⁰ to preserve the hybrid layer from degradation. Furthermore, several studies indicate that a 2% CHX or a CHX-containing phosphoric acid for etch-and-rinse adhesive systems may be an excellent method for increasing the long-term stability of collagen fibrils in the hybrid layer by inhibiting endogenous MMPs and cathepsins.^{268,269}

It has been demonstrated that the use of ethylenediaminetetraacetic acid (EDTA) inhibits MMP-2 and MMP-9 when applied for 1 to 5 minutes,^{260,272} while one in vitro study indicated an application of EDTA preserved the dentin-adhesive interface.²⁶⁶ Thus, the use of EDTA has been indicated as a dentin pretreatment for dentin adhesives.^{212,266} However, one study demonstrated that prolonged rinsing with water removes the EDTA and there may be no residual EDTA to inhibit the degradation by endogenous MMPs.²⁶⁰ Several studies indicate that an increase in the extent of cross-linking of the collagen fibrils prior to adhesive application may increase the potential for durability, while other studies indicate that cross-linkers enhance the mechanical properties of these substrates. Cross-linking agents have been purported to have anti-MMP properties,^{253,257} thus reducing enzymatic degradation.²⁷³ However, the application time for desirable therapeutic effect is not feasible,^{279,280}

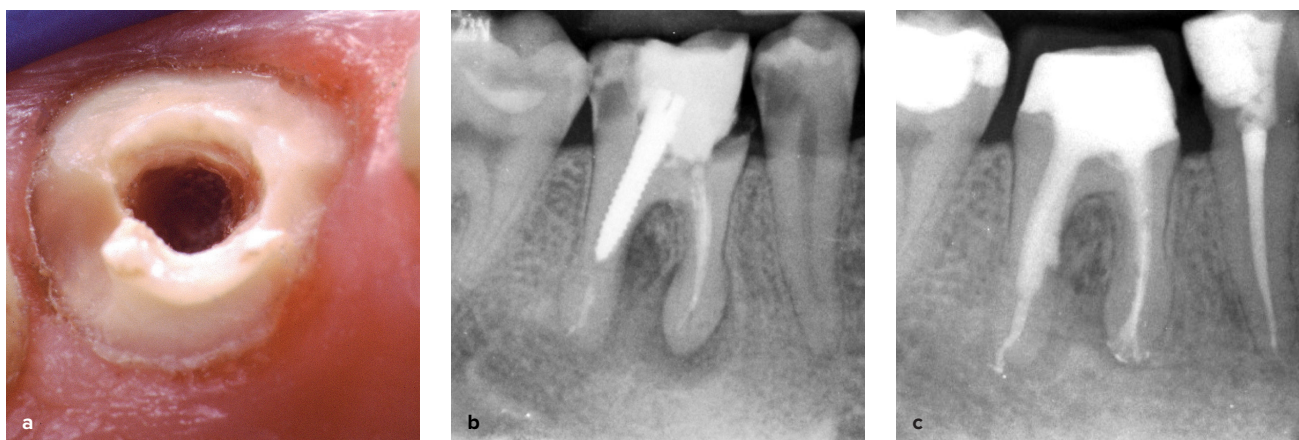

Fig 1-6 (a) Overpreparation of the post space to accommodate a larger selected fiber-reinforced post can weaken the remaining tooth structure and increase the potential for root fracture. (b) Root perforation caused by improper preparation and placement of an oversized post. (c) Repair of the perforation seen in b. (Dentistry in b and c courtesy of Riccardo Tonini, MD, DDS.)

and modification into a simplified protocol using proanthocyanidins incorporated into etchants and adhesives is recommended.^{254,256,258,259} Several studies indicate the use of benzalkonium chloride (BAC) or BAC-containing acid or adhesives to inhibit the activity of the endogenous MMPs.^{264,271} Because the root canal anatomy can impose limitations to achieving a quality hybrid layer, modified clinical protocols may have positive implications for improving the quality of the adhesive interface and the long-term adhesion of fiber-reinforced post systems to dentin. This in turn can improve the structural integrity of the remaining radicular dentin and increase the retention and resistance to displacement^{55,168,281} while dissipating and reducing functional stresses along the entire adhesive interface, thus providing maximum post retention and core stability.















Conservation of tooth structure

Numerous in vitro studies support evidence that conservation of sound tooth structure is the most important factor to the successful management of structurally compromised ETT.^{47,51,216,282–288} It is well supported in the literature that the longevity of an ETT is directly related to the amount of remaining sound tooth structure.^{29,43,289} However,

traditional-cast post systems and prefabricated post systems often require the removal of undercuts for a proper path of insertion and adaptation to the canal wall. This enlargement of the post-endodontic channel throughout biomechanical preparation during and after the endodontic procedure removes dentin during cleaning and shaping of the canal. The removal of additional dentin to accommodate placement of a larger post diameter significantly weakens the remaining tooth structure^{175,285,290} (Fig 1-6). This widening of the canal decreases the thickness of the root wall, which can lead to a diminished wall stiffness that results in increased stress levels^{291,292} and can compromise long-term success.^{293,294} It is widely accepted that 1 mm of dentin wall thickness is required to prevent root fracture and to properly support the core.^{159,295}

Additionally, during post channel preparation, the preservation of 4 to 5 mm of gutta-percha is necessary to provide an adequate apical seal.^{201,296–307} Several techniques for preparing the post channel and the effect of each technique on the apical seal have been investigated and include the use of rotary instruments, heated instruments, and solvents.^{175,299,304,308–310} An improper access preparation with too wide an enlargement when performing endodontic therapy can result in an excessive loss of sound coronal

Table 1-1 General guidelines for post placement^{300,337–339}

Tooth type	Number of roots/ canals	Anatomical root canal variations*	Cervical cross section	Preferred root canal for post channel placement	Cervical cross- sectional shape of the preferred canal
Central incisor					
Maxillary	One root, one canal	99.4%		Main single canal	Circular, ovoid
Mandibular	One root, one canal One root, two canals	73.6% 26% incidence of second canal usually lingual to the main canal		Main single canal	Ovoid, ribbon-shaped
Lateral incisor					
Maxillary	One root, one canal	93.4%		Main single canal	Circular, oval, or ovoid
Mandibular	One root, one canal One root, two canals	71.8% broad buccolingually and narrow mesiodistally 28.1% incidence of second canal usually lingual to the main canal		Main single canal	Ovoid, ribbon-shaped
Canines					
Maxillary	One root, one canal	96.5%		Main single canal	Oval
Mandibular	One root, one canal	94.8%, 89.4% (10.6% incidence of second canal usually lingual to the main canal)		Main single canal	Ovoid
First premolars					
Maxillary	One root, one canal Two roots, two canals Three roots, three canals	52.2%, 21.3% 46.7%, 75.8%; mesial developmental root depression; root concavities are present on both mesial and distal surfaces of the root 1.15%, 1.4%		Main single canal Palatal root	Round, ovoid
Mandibular	One root, one canal	97.9%, 72.2%		Main single canal	Ovoid
Second premolars					
Maxillary	One root, one canal	90.7%, 50.3%; developmental depressions are often present on the mesial and distal aspects of the root		Main single canal	Ribbon-shaped, elliptical
Mandibular	One root, one canal	99.6%, 91.1% (8.9% incidence of second canal)		Main single canal	Ovoid
First molars					
Maxillary	Three roots, three canals	95.9%; mesiobuccal 42.9%; two mesio- buccal canals 57.1%; distobuccal 98.3% (only variation in mesiobuccal canal)		Palatal root	Circular, ovoid
Mandibular	Two roots, three canals	85.2%; two mesial canals (100%); distal root one canal (68.3%)		Distal root	Ovoid
Second molars					
Maxillary	Three roots, three canals	88.6%; mesiobuccal 52.9%; distobuccal (99.7%); palatal (99.9%)		Palatal root	Circular, ovoid
Mandibular	Two roots, three canals One root	76.2%; two mesial canals (86%); one distal (85.1%) C-shaped (8.5%) and single conical roots (8.3%)		Distal root Main single canal	Elliptical, C-shaped C-shaped

This table indicates anatomical root canal variations in Asian and non-Asian populations. However, anatomical variations exist in different subpopulation groups. The table provides the necessary information for post preparation and placement. During post channel preparation, the preservation of 4 to 5 mm of gutta-percha is necessary to provide an adequate apical seal.^{201,296–307}

*If there are two numbers, the first number is the prevalence for that number of roots for a given tooth, and the second number is the prevalence for that number of canals for said tooth among the population groups studied.

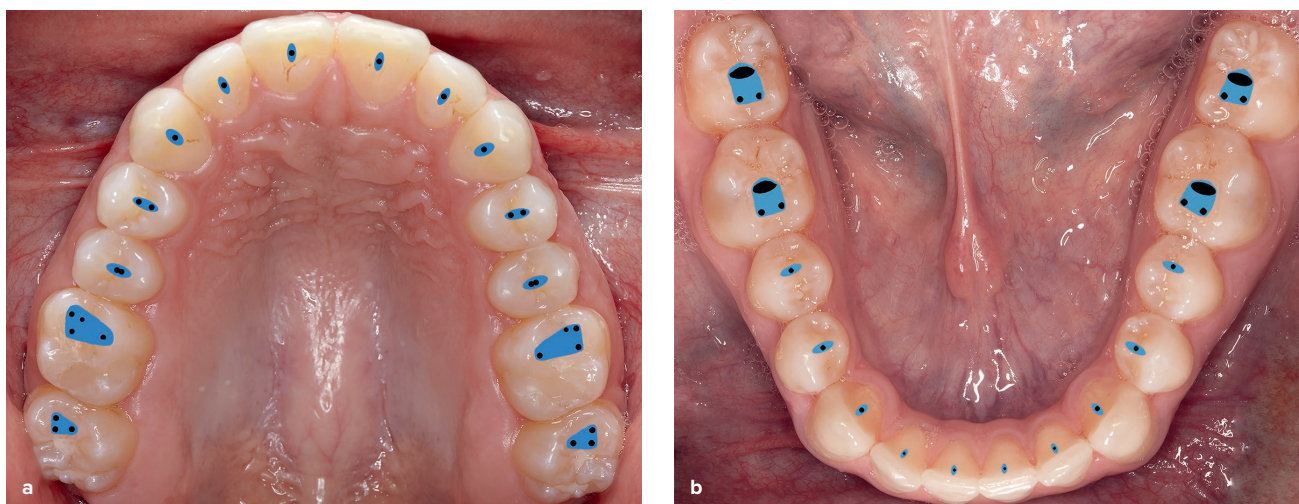


Fig 1-7 (a and b) Conservative endodontic access openings.

tooth structure^{20,40,311,312} and increase the occurrence of fractures^{43,206,291,313} (Fig 1-7). In addition, endodontic access on a tooth with loss of one or both marginal ridges increases the potential for fracture.^{29,44,314–317} Investigators have reported that rotary instruments caused more dentinal defects, such as craze lines and partial cracks, which have the potential to develop into fractures after endodontic and restorative treatment.^{318–320} However, no defects were observed with hand file instrumentation.³¹⁸ Furthermore, overpreparation of the post space and the utilization of larger posts decrease the resistance to fracture.^{51,285,287} This reduction in the amount of dentin weakens the structural integrity of the tooth²¹⁶ and can be responsible for horizontal and vertical root fracture.^{291,321–326} To prevent overpreparation during the endodontic or restorative procedure, it is recommended that the root morphology be considered for each tooth type prior to treatment. Mandibular incisors, maxillary second premolars, and the distal root of mandibular molars have mesiodistal concavities and may be narrower mesiodistally than they appear in the radiograph.³²⁷ A CBCT image can provide a 3D visualization of these anatomical features in cross section and reduce the potential for a weakened

structural integrity or root perforations³²⁸ by providing a view of the tooth anatomy. Because of the wide range in anatomical variation in regard to number and shape of roots and root canals for each tooth type,^{329–335} a comprehensive knowledge of root morphology^{179,336} and an understanding of external root anatomy can provide insight for selecting the teeth and roots that are most appropriate for post placement with less potential for thinning and root fracture³⁰⁰ (Table 1-1; for further information, see section entitled “Guidelines for Restoring the Intraradicular Space”^{300,337–339}).

Improvements in composite materials, adhesive technology, and endodontic procedures and technology have resulted in a more conservative design concept.⁹ This minimally invasive concept preserves intact tooth structure, reducing the potential for failure²⁰⁹ while providing adequate retention and resistance form for the final restoration.⁴⁰

One method of the direct fiber-reinforced resin post system (see section entitled “Direct Fiber-Reinforced Post and Core System”) allows preservation of the canal structure and can be utilized in the treatment of irregular canal configurations. This procedure does not require a converging path of insertion and can be used with minimal preparation

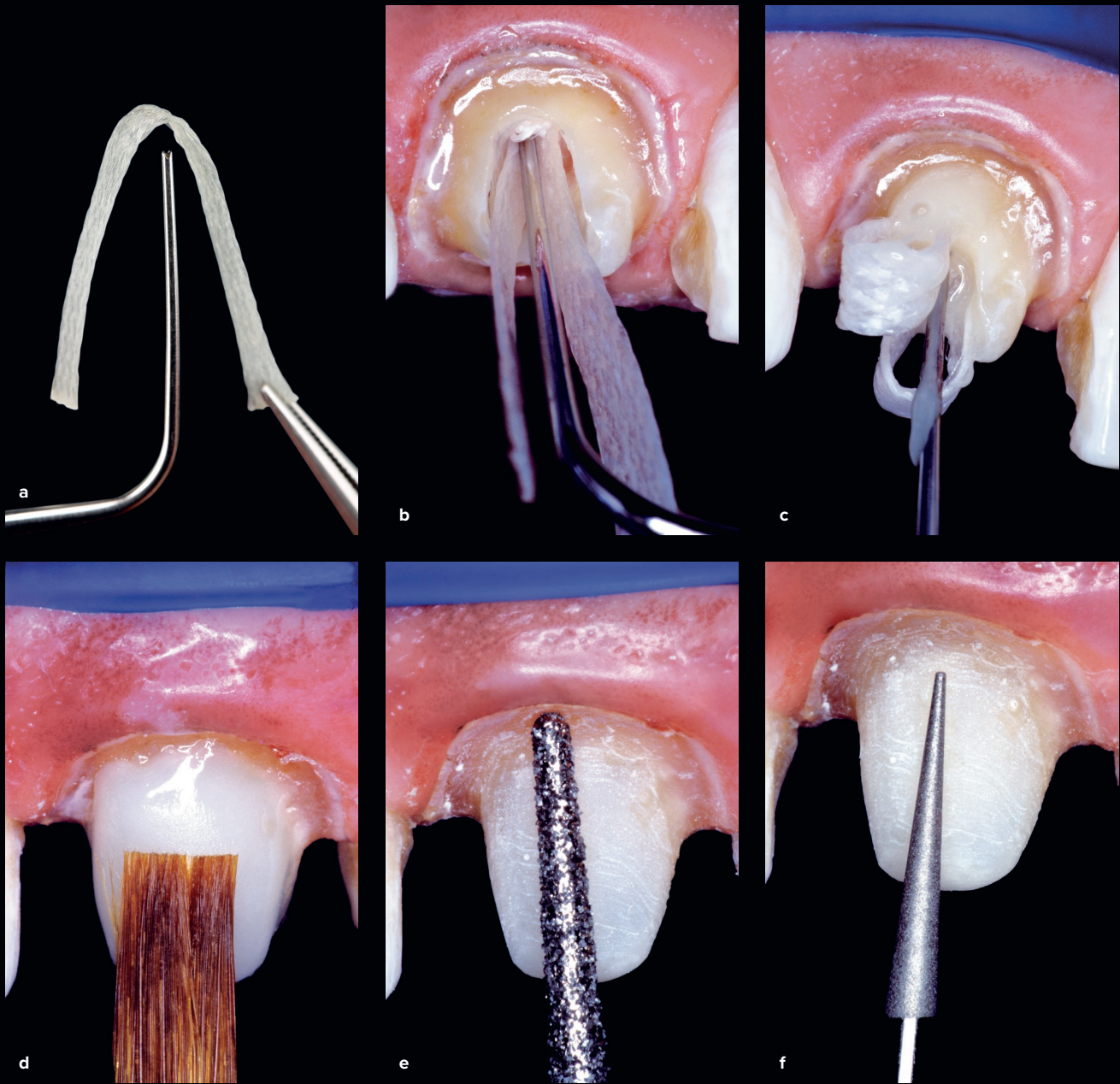


Fig 1-14 (a) A modified Luk's gutta-percha condenser can be used for placement of the 2-mm gas plasma-coated fiber ribbon (Ribbond-THM). (b and c) After a dual-cured composite resin cement is injected into the post channel, the reinforcement fiber is placed to the base of the post channel, and the ends of the fiber are folded back into the channel and arranged into the desired shape of the core and light cured for 60 seconds. (d) A dual-cured or light-cured composite is injected over the coronal fibers, and the composite material is adapted, sculpted, and smoothed with a #2 sable brush into the desired form and dimension of an ideal preparation. (e) The preparation is completed using a tapered diamond (6850-31-018, Brasseler USA). (f) Finishing and smoothing of the preparation is accomplished using a fine 8-mm diamond bur (DET6, Brasseler USA).

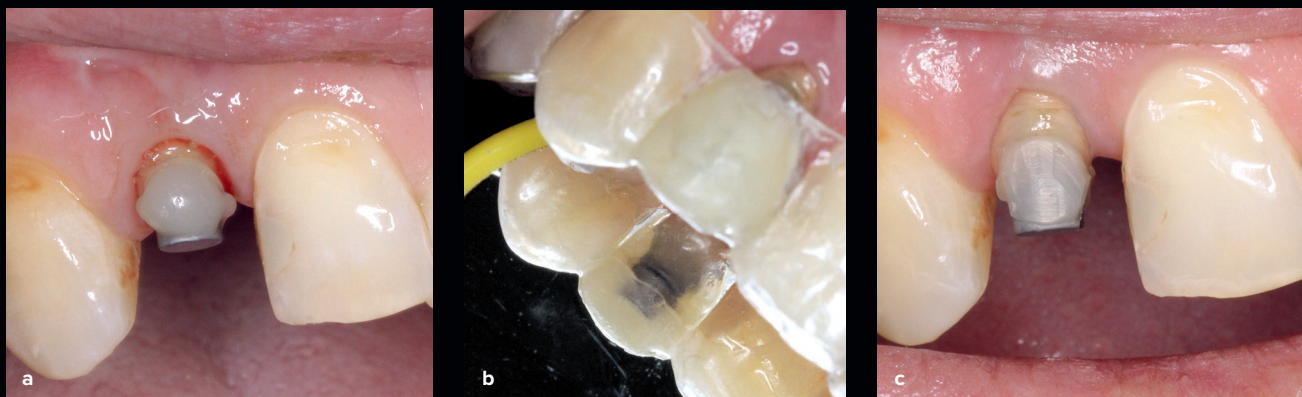


Fig 1-25 (a to c) After endodontic therapy and placement of a fiber-reinforced post on the maxillary right lateral incisor, orthodontic extrusion was accomplished using magnets. (Dentistry courtesy of Abdelrahman Awadin, BDS.)

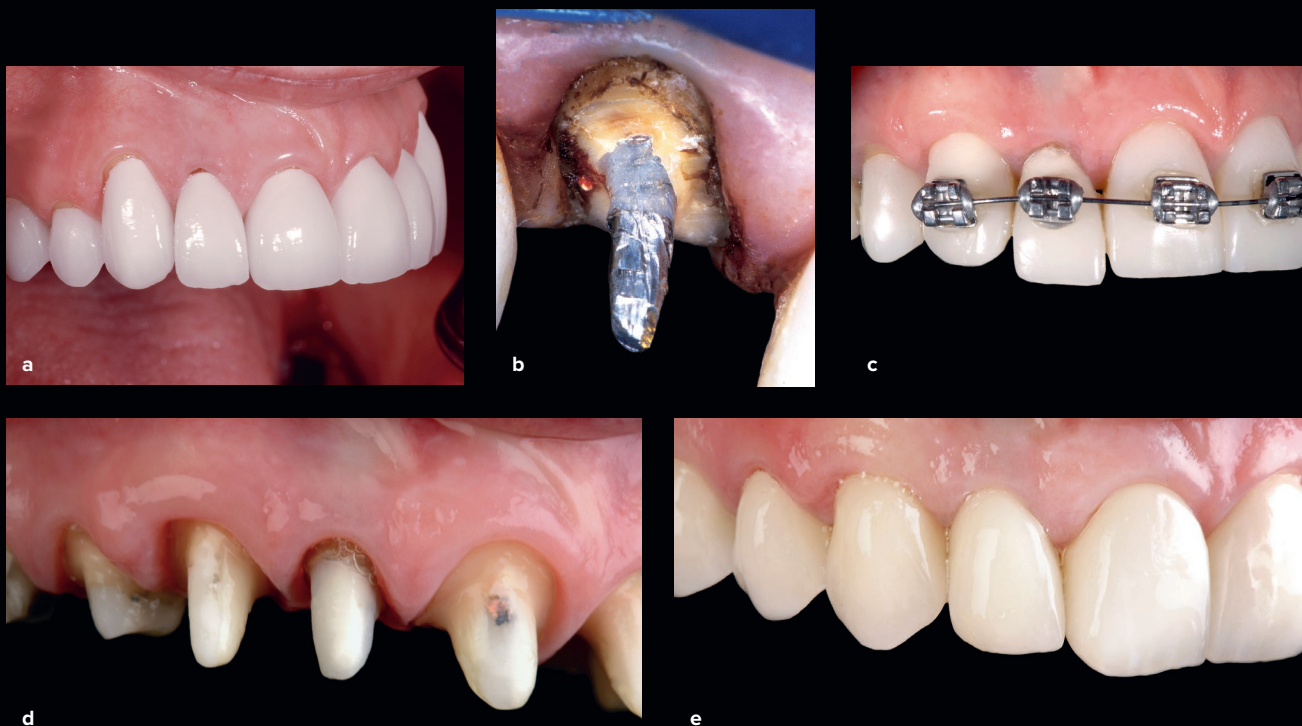
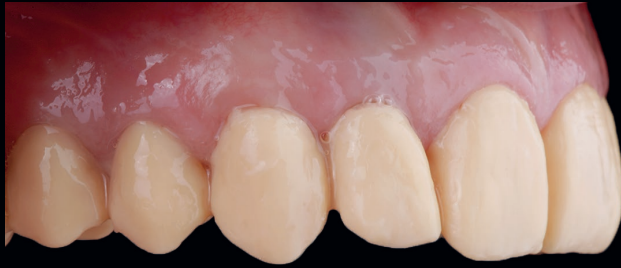
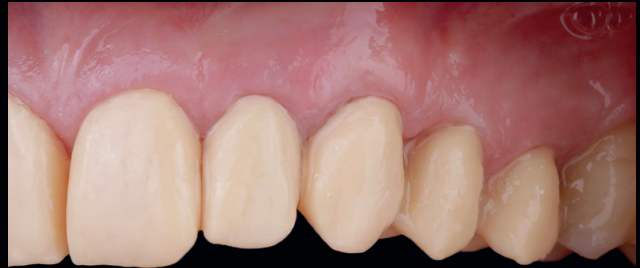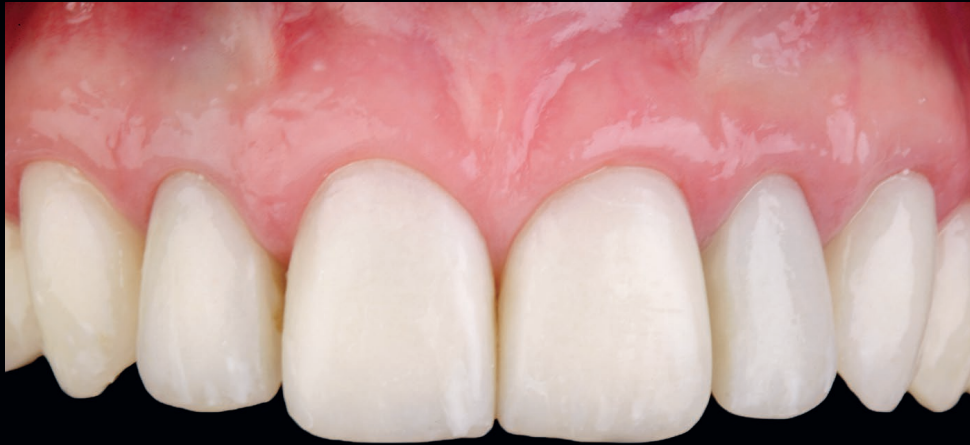Fig 1-26 Orthodontic extrusion can be used to establish an optimal ferrule height, biologic width space, and an ideal gingival architecture. (a and b) During previous treatment, the endodontically treated maxillary right lateral incisor had insufficient ferrule height, and the restorative margin was placed in violation of the biologic width. (c and d) Orthodontic brackets were placed on the provisional restorations, and the maxillary lateral incisor was extruded to attain a ferrule dimension of 1.5 mm and to establish a biologic width of 3 mm. The more rapid the movement, the less likely it is to extrude the supporting structures. (e) Note the healthy biologic framework achieved by attaining a restorative dimension of 4.5 mm of supracrestal tooth structure. For more information, see chapter 2, Case 1.



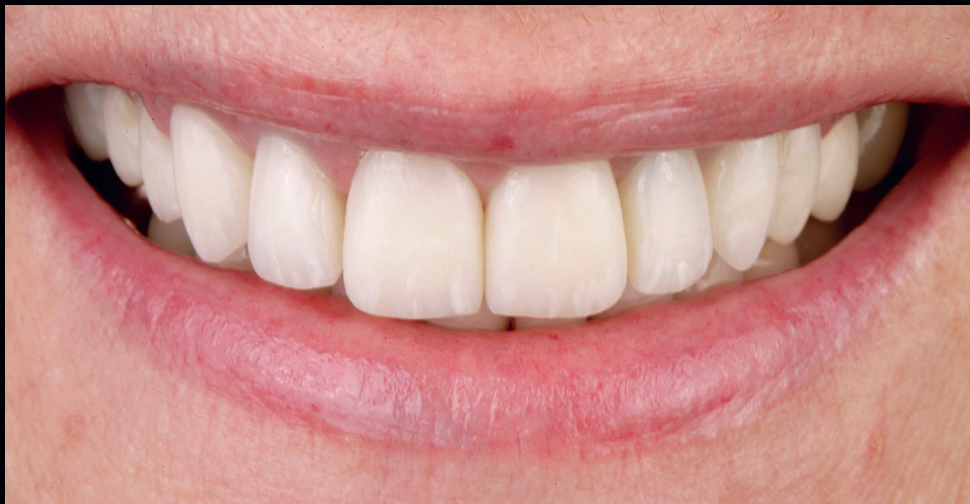33



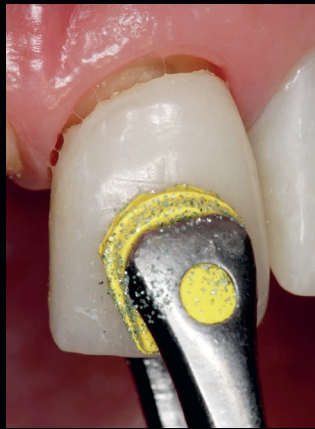34



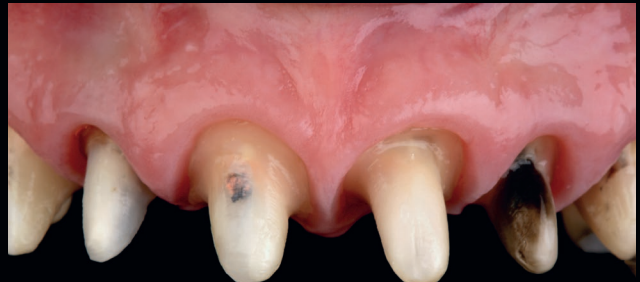35



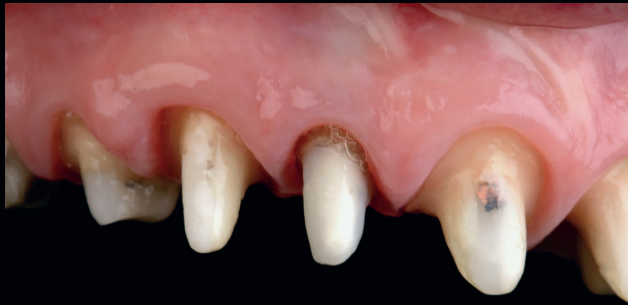36



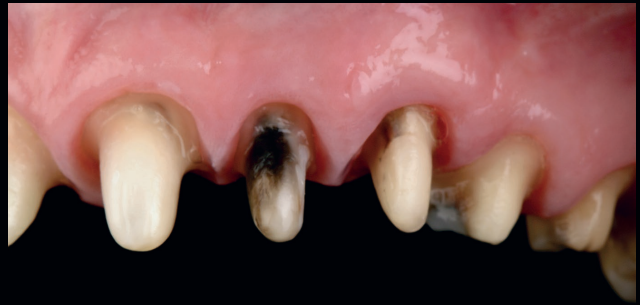41



42



43

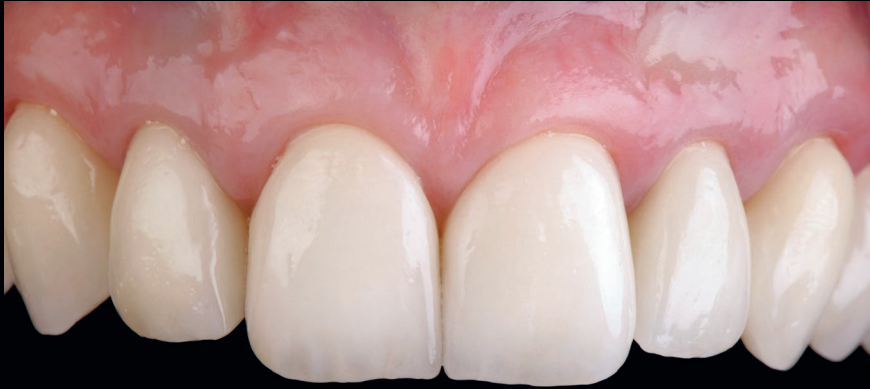

44

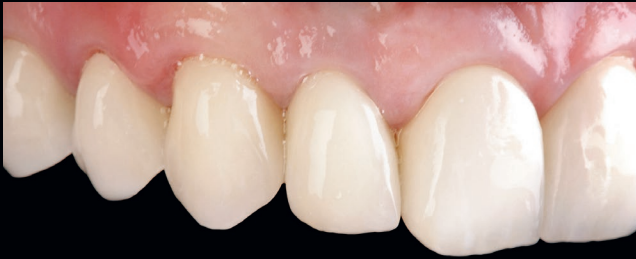The provisional restoration preserves the position, form, and color of the gingiva and maintains the periodontal health while the definitive restoration is being fabricated. At the try-in visit, the provisional restorations can be removed using a crown-removing instrument (GC Pliers, GC America) with an emery powder (Fig 41). It is important to dry the provisional restoration before applying the powder. A properly contoured and sealed provisional restoration allows the development of a healthy soft tissue framework (Figs 42 to 44).

The porcelain restorations were tried in and evaluated, and modifications were completed prior to beginning the adhesive process. To prevent contamination during the adhesive procedure, a 30 silk cord (30 Silk Suture) was

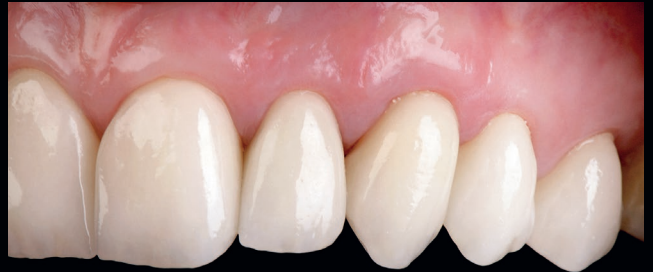gently placed in the sulcus using a bimanual technique (Figs 45 and 46). This silk cord seals the sulcus and prevents contamination of the preparation from blood or crevicular fluid during the adhesive protocol. The internal surface of the zirconia crowns were microetched with a tribochemical silica coating (Rocatec/CoJet System, 3M), followed by an application of a 10 MDP-containing bonding/silane coupling agent mixture (Porcelain Bond Activator mixed with Clearfil SE Bond Primer; Figs 47 and 48). The microetching of highly crystalline ceramics such as zirconia with a tribochemical silica coating creates binding sites for the silane molecules, while the silane provides wettability and a chemical coupling with the methacrylate-based cements.



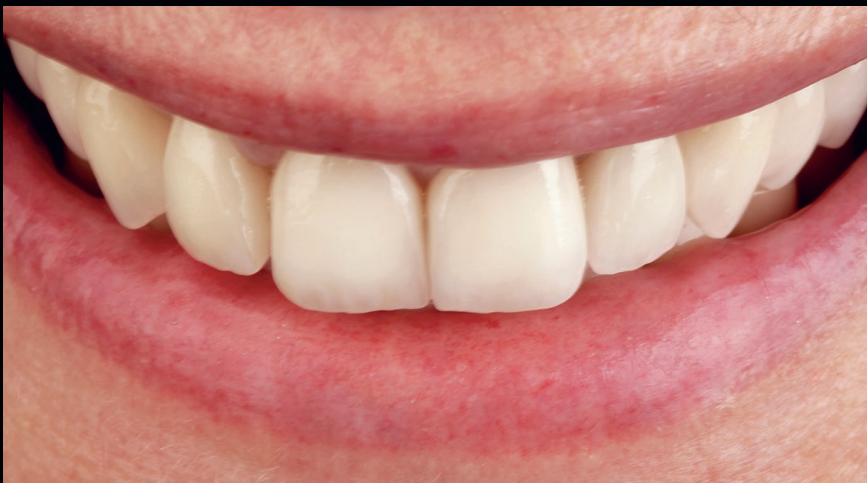58



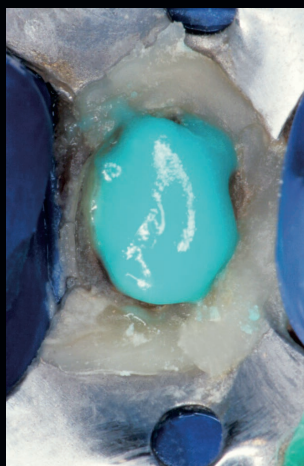59



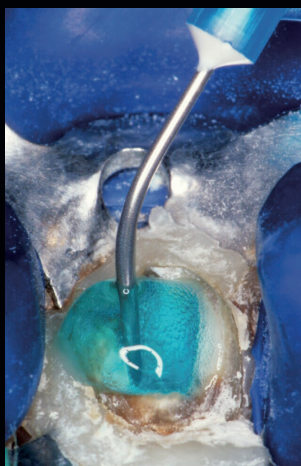60



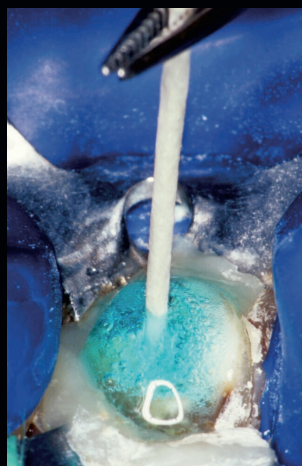61



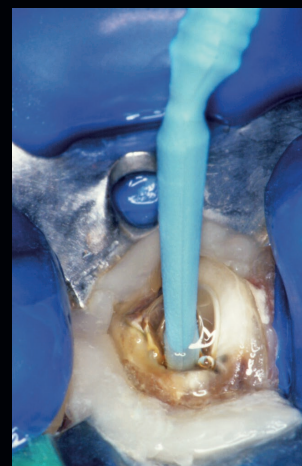
6



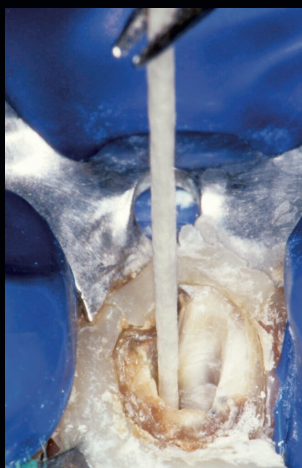
7



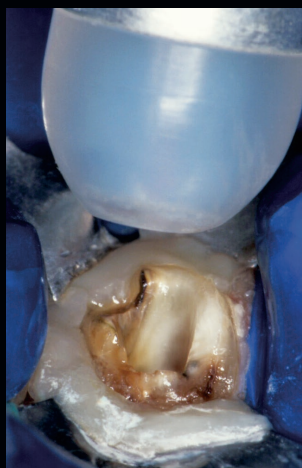8



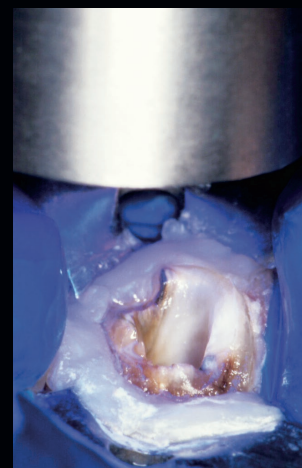
9



10



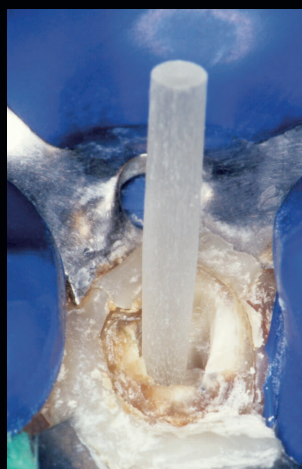
11




12

the post space and to the most apical areas (Figs 9 and 10). The adhesive was lightly air thinned using a warm-air tooth dryer and light cured for 40 seconds (Figs 11 and 12). The preselected fiber post (#2 D.T. Light-Post, Bisco) was placed into the post channel, and the coronal height was measured and marked with a diamond disk to the desired length (Figs 13 and 14). The proper orientation was verified by rehearsal of the post placement. An adhesive (All-Bond 3, Bisco) was applied to the post, gently air dried, and light cured for 10 seconds.

A dual-cured composite resin cement (Duo-Link, Bisco) was injected into the post channel with a needle-tube syringe (AccuDose NeedleTubes, Centrix), which was slowly removed during the injection to prevent the incorporation of



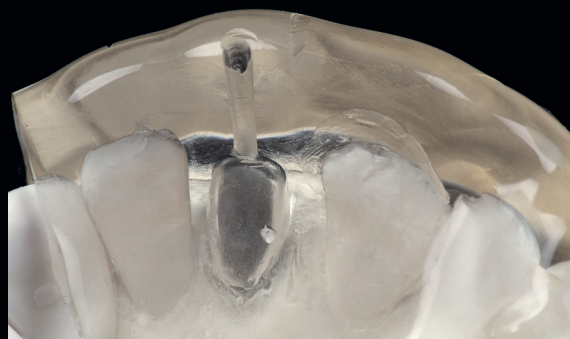13



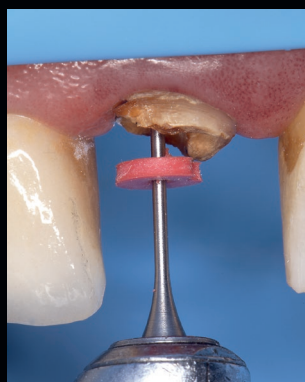
14



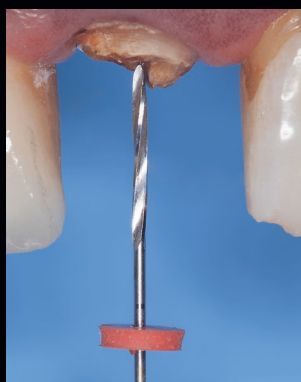
7



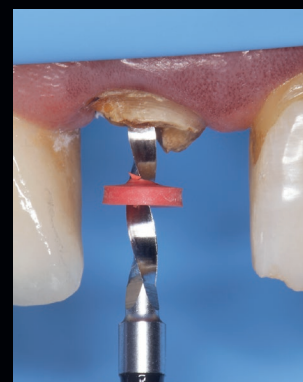8



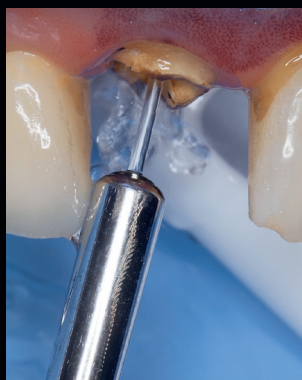9



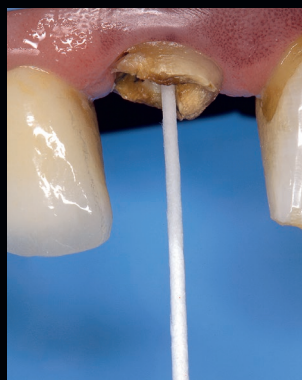10



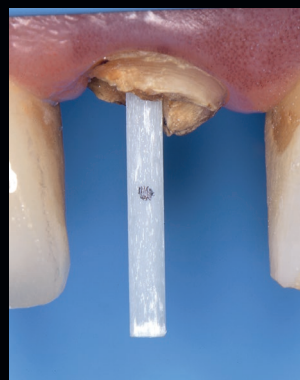11



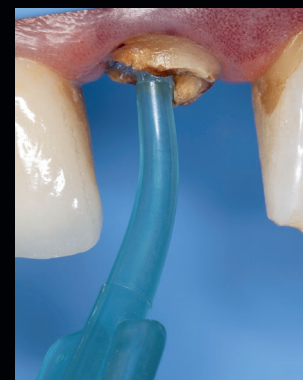12



13



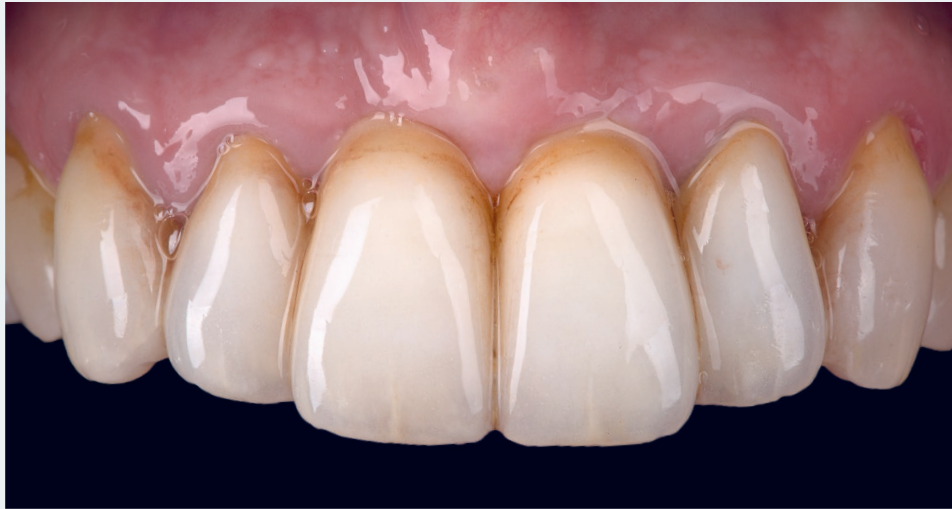14



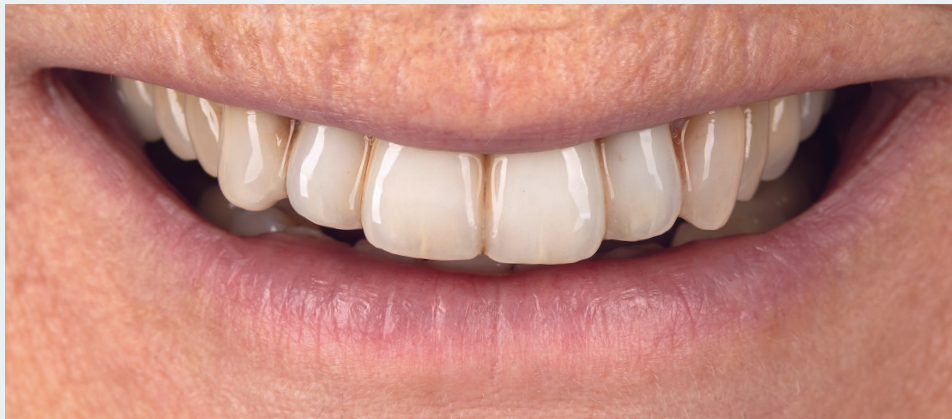15

for the formation of voids and bubbles in the impression material. A small opening was made above the tooth to be restored using a tapered diamond bur (6847; Figs 7 and 8). It is important to clean the internal surfaces with a microbrush to prevent silicone debris incorporating into the flowable material.

After determination of the desired post channel length (one-half to two-thirds the length of the canal), a dental dam was placed using the modified dam technique. The gutta-percha was removed with a series of preshaping instruments (Gates Glidden, Rebilda Post Reamers, VOCO; Figs 9 and 10), and the channel preparation for a prefabricated



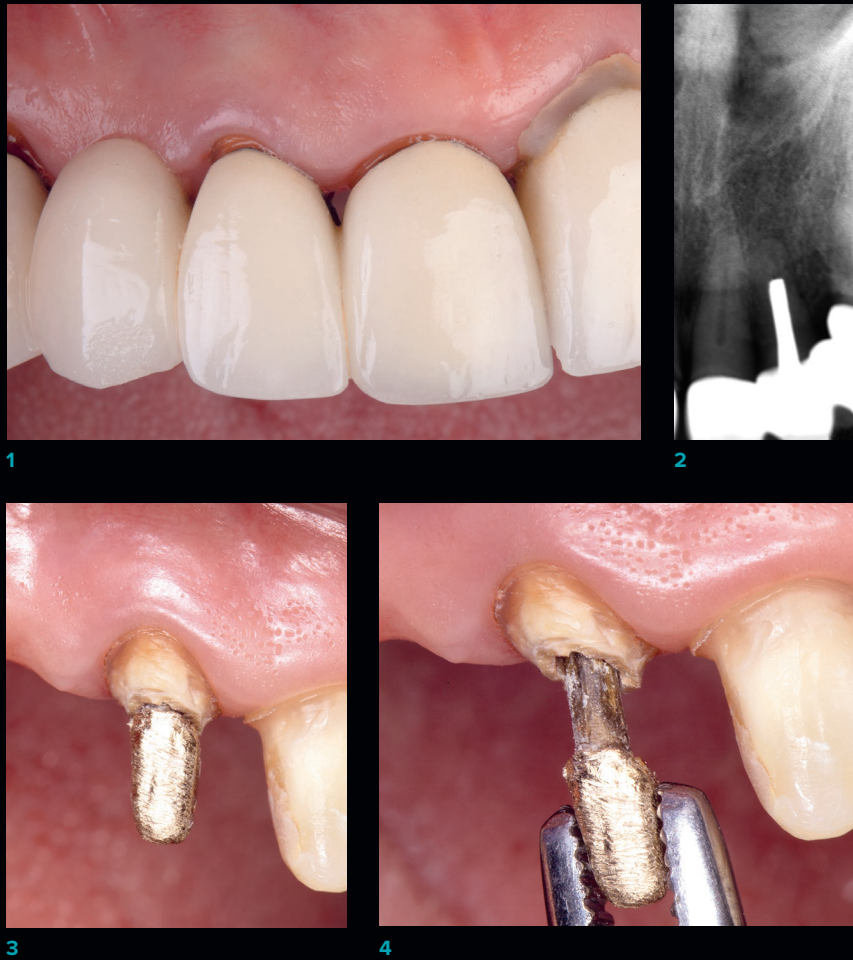
36



37

Laboratory work courtesy of Jungo Endo, RDT

5. Abduljawad M, Samran A, Jadalkareem K, Al-Afandi M, Ghazal M, Kern M. Effect of fiber posts on the fracture resistance of endodontically treated anterior teeth with cervical cavities: An in vitro study. *J Prosthet Dent* 2016;116:80–84.
6. Mangold JT, Kern M. Influence of glass-fiber posts on the fracture resistance and failure pattern of endodontically treated premolars with varying substance loss: An in vitro study. *J Prosthet Dent* 2011;105:387–393.
7. Saupe WA, Gluskin AH, Radke RA Jr. A comparative study of fracture resistance between morphologic dowel and cores and a resin-reinforced dowel system in the intraradicular restoration of structurally compromised roots. *Quintessence Int* 1996;27:483–491.
8. Agrawal A, Mala K. An in vitro comparative evaluation of physical properties of four different types of core materials. *J Conserv Dent* 2014; 17:230–233.
9. Magne P, Goldberg J, Edelhoff D, Guth J-F. Composite resin core buildups with and without post for the restoration of endodontically treated molars with ferrule. *Oper Dent* 2015;41:64–75.
10. Magne P, Carvalho AO, Bruzi G, Anderson RE, Maia HP, Giannini M. Influence of no-ferrule and no-post buildup design on the fatigue resistance of endodontically treated molars restored with resin nanoceramic CAD/CAM crowns. *Oper Dent* 2014;39:595602.

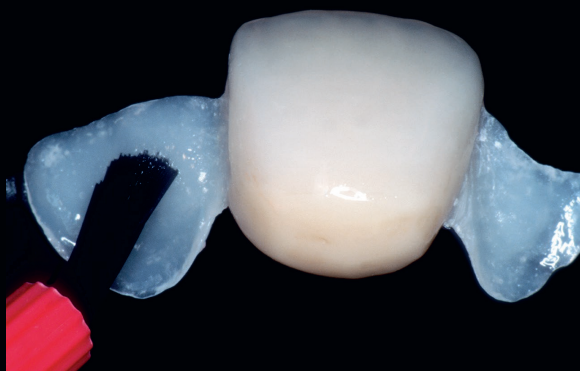


REPLACEMENT OF A GOLD POST IN THE ESTHETIC ZONE

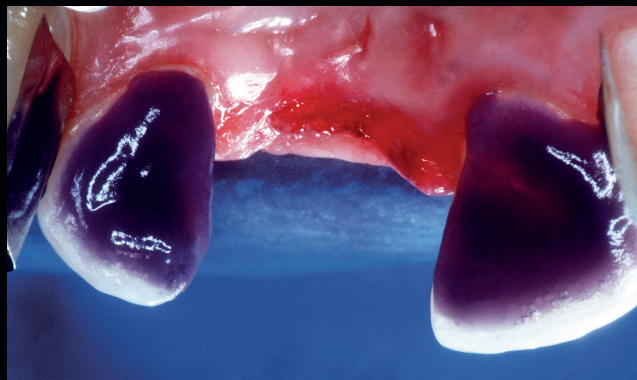
The patient presented with an anterior FPD with marginal discrepancies and recurrent caries (Fig 1). She indicated that the prosthesis had dislodged and was recemented several times. Upon clinical and radiographic evaluation, it was determined that the substructure on the maxillary lateral incisor was a custom fabricated gold post (Fig 2). After removal of the metal-ceramic crown, the gold post was easily removed (Figs 3 and 4).

Clinical evaluation of the remaining tooth structure indicated only sclerotic and discolored dentin with no caries

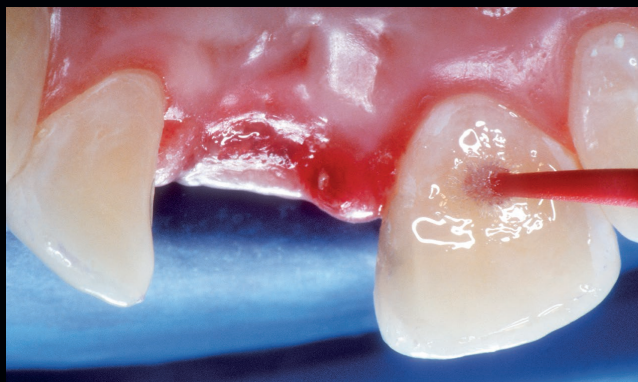present (Fig 5). Therefore, an adequate ferrule design of 3 to 4 mm of tooth structure was available for resistance and retention form. However, because of the overpreparation from the previous post preparation and placement, a conservative endodontic retreatment and channel preparation was necessary to avoid further infringement on the channel wall. After endodontic retreatment, the patient returned for post preparation. Dental dam was placed using the modified dam technique, and a series of Gates Glidden drills (#1, #2, #3) was used to remove the gutta-percha (Figs 6 and 7). The length of the post channel was established as two-thirds the length of the root while maintaining an adequate apical seal. An endodontic reamer the size of the existing



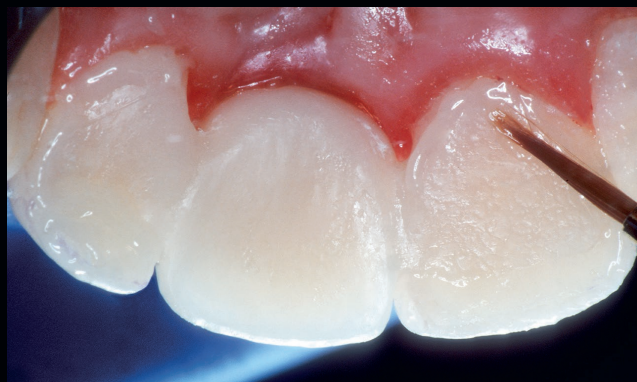15



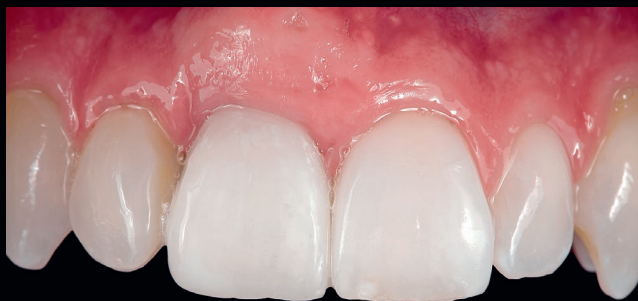16



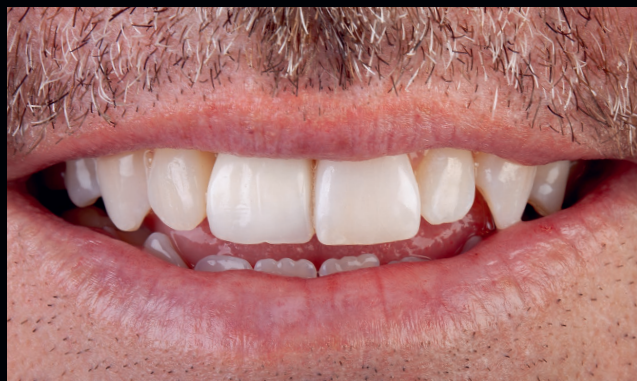17



18



19

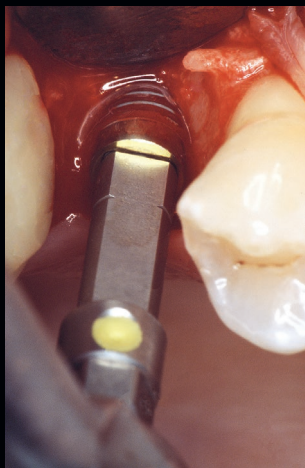


20

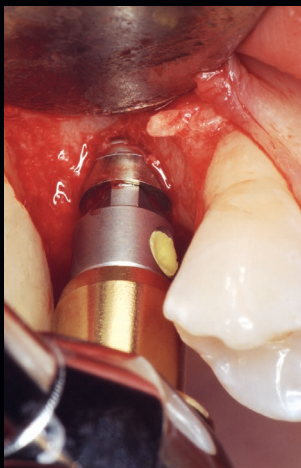
the restoration was gently positioned into place. The excess resin cement was removed using a #000 sable brush while a residual amount of resin cement was left at the margin to compensate for polymerization shrinkage (Fig 18).

A 7-year follow-up of the socket preservation and ridge augmentation is shown in Fig 19. These procedures provide

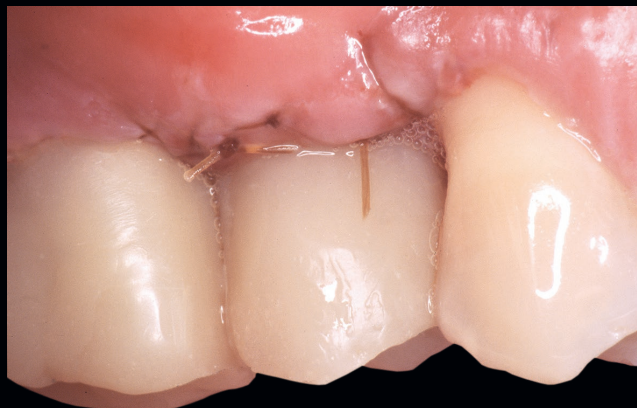preservation and augmentation of the maxillary anterior segment without implant placement. This minimally invasive restorative procedure can provide optimal biointegration of the resin-bonded restoration with the surrounding soft and hard tissue architecture. A natural smile was created with this interdisciplinary approach (Fig 20).



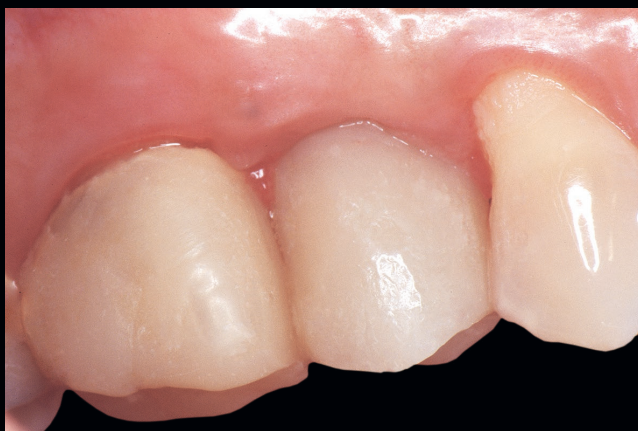28



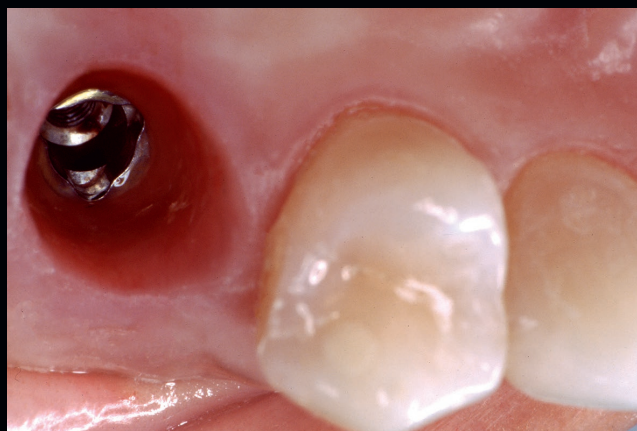29



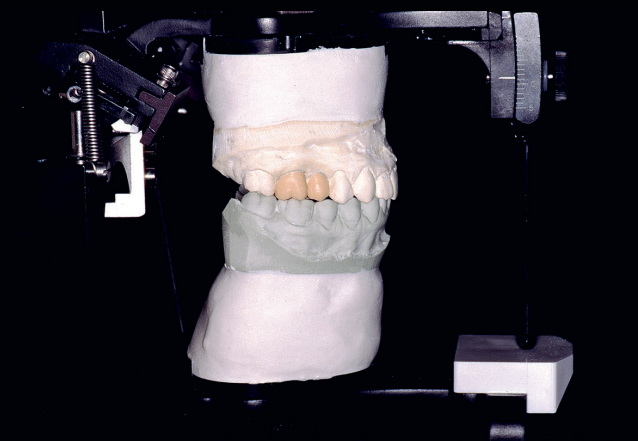
30



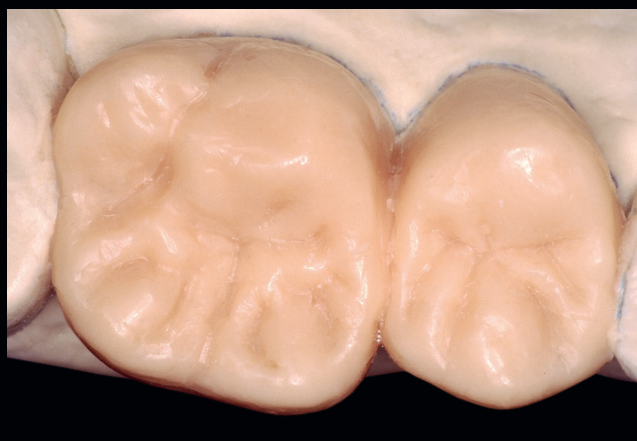31



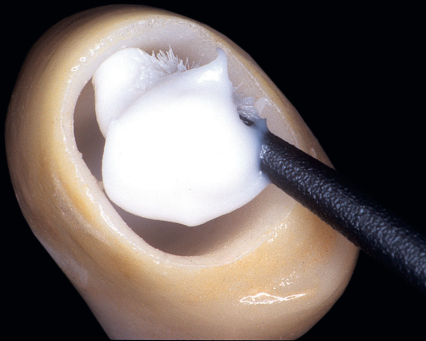
32



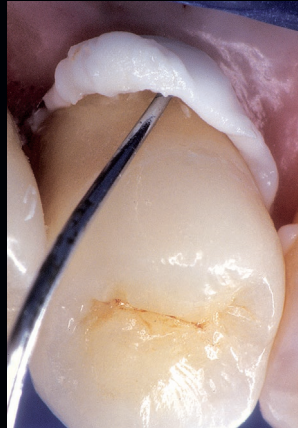33



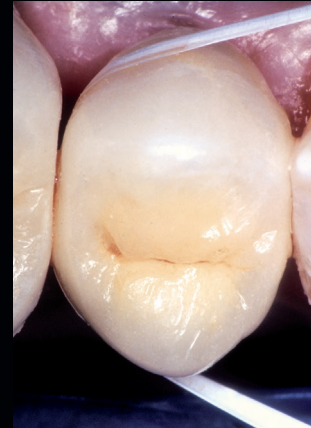
34



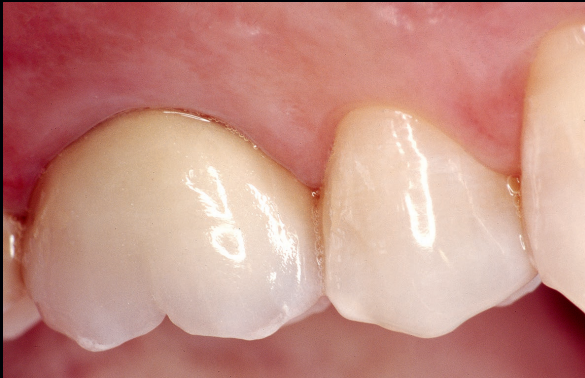46



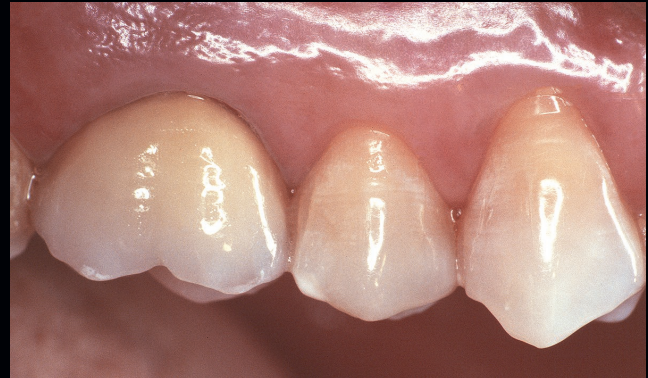47



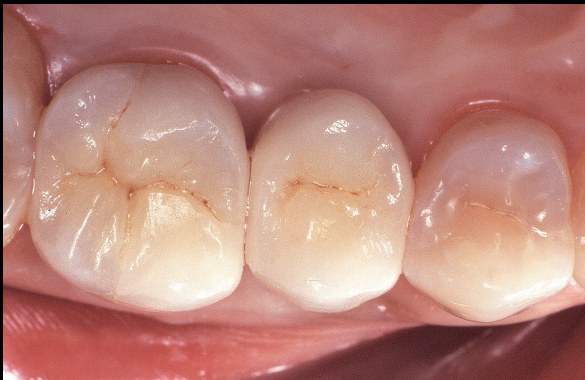48



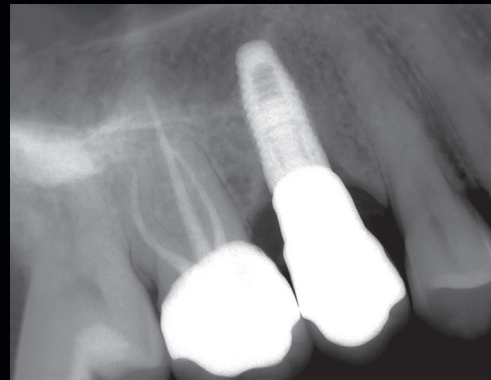
49



50



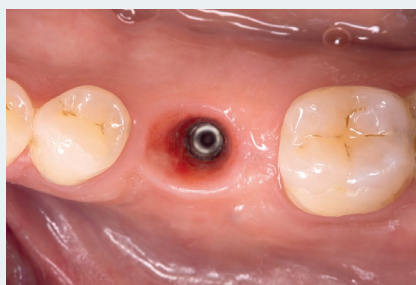51



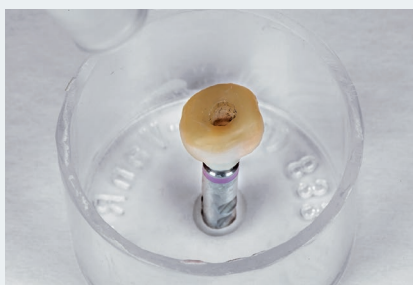52

Two-year postoperative views illustrate an ideal peri-implant biointegration of the peri-implant architecture (Figs 49 to 51). For long-term stability and natural soft tissue esthetics, a biologic balance is required in the peri-implant

zone and must correspond to the soft tissues that surround the adjacent teeth. A 10-year postoperative radiographic review reveals dense, mature bone with a healthy and functional peri-implant support system (Fig 52).



39



40



41




42



43



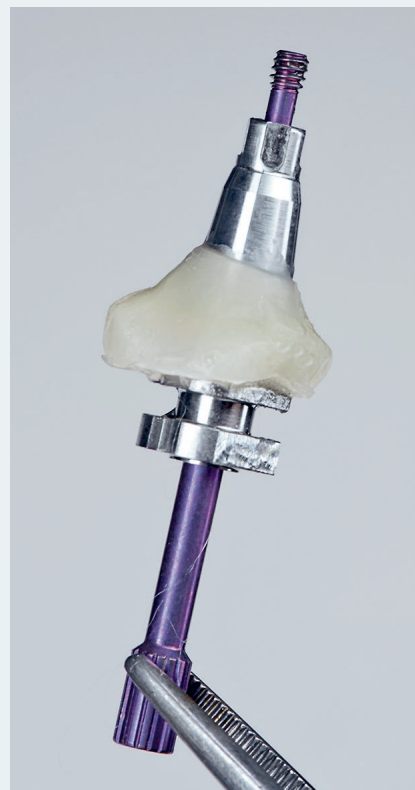44



45



46



47

and was screwed onto an implant analog (Figs 39 and 40). A polyvinyl siloxane impression material was injected around the abutment and allowed to set (Figs 41 and 42). After the impression material was set, the customized healing abutment was removed, and an impression post was screwed onto the implant analog (Fig 43).

A flowable resin composite (G-aenial Universal Flo, GC America) was injected into the spaces between the impression material and the impression post and light cured with an LED curing light for 60 seconds (Figs 44 and 45). The assembly was removed, and now the impression post had the same shape and contour as the customized healing abutment (Figs 46 and 47). The correctness of the transfer can be checked against the soft tissue contour with the